



Evaluation of nephroprotective activity of sirupeelai kudineer (*Aerva lanata* decoction) in rats

G. S. Lekha

Siddha Central Research Institute (SCRI), Central Council for Research in Siddha, Arumbakkam, Chennai, Tamil Nadu, India

ABSTRACT

The herbal drug Sirupeelai Kudineer, basically the decoction of whole plant- *Aerva lanata*. Linn -the plant which is being commonly used in Siddha System of Medicine, is evaluated for Nephroprotective activity in animal model. To evaluate the efficacy of Sirupeelai Kudineer in the management of Renal function Impairment. The Nephroprotective activity of the drug in Gentamicin models was evaluated in Wistar albino rats. The rats in prophylactic group were treated with the decoction of *Aerva lanata* at the dose of 270 mg (5.4 ml) and 500 mg (10.0 ml)/ kg. The Gentamicin models of rats treated with the drug at the dose of 500.0 mg/kg orally for 10 days showed significant reduction in the level of Blood urea ($P < 0.02$) and Serum Creatinine with the significance of ($P < 0.05$). Histopathology also reveals the reduction in the degree of renal damage. These findings suggest that the drug possess Nephroprotective activity with minimal toxicity and could offer promising role in the management of renal damage caused by Nephrotoxins like Gentamicin.

Key words: Nephroprotective, Sirupeelai, Kudineer, Nephrotoxins, Aminoglycosides (AG), Gentamicin.

INTRODUCTION

In the medical field Impairment of renal function is one of the challenging problem causing mortality and morbidity, for which the replacement therapy (dialysis or transplantation) becomes necessary, and is associated with complications in virtually of all organ systems. Hence there is a continuous search for agents which provide protection against the renal impairment caused by drugs. This fact drove the author to go for a native solution through *Sirupeelai Kudineer*.

Sirupeelai is the well known herb being used by many Siddha practitioners. In general, the Plant *Aerva lanata* has significant Pharmacological activities like Diuretic, Anti-inflammatory and Lithotriptic action.[1] The Antioxidant, Cytotoxic and Hepatoprotective activity of *Aerva lanata* has also been demonstrated by Scientific studies and published in Journals. The plant contains flavanoids such as Kaempferol 3-rhamnoside and Kaempferol 3 – galactoside which are well known potent antioxidant and free radical scavengers. [2]

As per the Siddha Literatures the herb *Sirupeelai* is indicated for *Neeradaippu*[3] - the pathological conditions of which can easily be correlated with the Impairment of Renal function. Moreover *Sirupeelai* was mentioned as '*Uppu chathai nasamakki*' in the Siddha text *Bohar Nigandu* 1200 [4] which means that this drug can remove the metabolic waste products from blood. These Siddha Literary evidences makes the author to evaluate the Nephroprotective action of *Aerva lanata* decoction in rats.

The Plant *Aerva lanata* have been evaluated for various pharmacological activities. The acute toxicity and behavioural pattern studies with different doses of Aqueous extract of *Aerva lanata* (AAL) 0.5 – 4 gms / kg, p.o.

showed no visible symptoms of toxicity at a dose as high as 4 g/kg. There were no signs of symptoms like restlessness, respiratory distress, diarrhoea, convulsions, coma, etc. (Laurence and Bacharach, 1964). [5]

As per one of the earlier studies, the partially purified petroleum ether extractable fraction of the whole plant *Aerva lanata* (PF) administration significantly reversed the histopathological changes and restored the elevated activities of liver marker enzymes and also enhanced the antioxidant enzyme activities. The extract also reduced hepatic lipid peroxidation and increased the serum total protein and albumin/globulin (A/G) ratio. Preliminary phytochemical analysis of PF showed the presence of alkaloids. These observations clearly indicate that *Aerva lanata* contains antioxidant alkaloids capable of ameliorating the CCl₄-induced hepatic injury by virtue of its antioxidant activity. [6] Another study reveals that, the partially TLC-purified fraction (PEF) of petroleum ether extract was proved to be cytotoxic to Dalton's lymphoma ascites (DLA), Ehrlich ascites (EA) and B16F10 cell lines *in vitro*. Consequently the animal study using the extracts of *Aerva lanata* showed significant reduction in the development of solid tumor in mice. [7]

Though the extracts of *Aerva lanata* have been screened for different pharmacological activities, no study has been reported to explore its activity on Renal function. Hence the decoction of *Aerva lanata* was evaluated for its Nephroprotective activity in Wistar albino rats.

EXPERIMENTAL SECTION

1.1. PREPARATION OF DRUG

1.1.1. Collection of Plant material and Authentication:

Plants were collected from Chennai Tambaram local area in the month of September 2006 was authenticated by Medicinal Botany department of National Institute of Siddha. The whole plants were washed in pure water, cut into small pieces and dried in sun shade. The dried plant is powdered and preserved.

1.1.2. Preparation of drug:

The powdered plant was boiled with water of four times that of drug and condensed into ¼th of it. The decoction was made in such a way that 1 ml of decoction contains 50 mg of drug i.e, 5% extract. The drug was daily prepared just before administration because of the short shelf life of the drug (3 hours).

1.2. BIOCHEMICAL ANALYSIS

The Biochemical analysis of the drug was done in Mettlex laboratories of India, Chennai – 32 to determine the metals and minerals in *Sirupeelai*, By means of Atomic Absorption Spectrometer (AAS) with air – acetylene.

The XRF analysis of the drug *Sirupeelai* was done in Central Electro Chemical Research Institute, Karaikudi.

1.3. PHARMACOLOGICAL STUDIES

The pharmacological action of the drug *Sirupeelai* was carried out in Central Research Institute for Siddha, Arumbakkam, Chennai. Study was conducted after obtaining Institutional Animal Ethical Committee clearance (Proposal No. 18 / PHARMA/CRIS, 2007).

1.3.1. Experimental Animals:

Healthy adult male albino rats (200 – 250gms) of Wistar strain were used for the study. The rats were housed in polypropylene cages and maintained under standard conditions (Temperature range: 65-75°F and Humidity range: 40-70%). The animals had free access to standard pellet diet (Amrut Laboratory Animal Feed, Nav Maharashtra House, Pune & Maharashtra) and water utilizing aqua guard.

1.3.2. Drugs and chemicals:

The chemicals used for the study are Gentamicin Injection (Merlin pharma (P) Ltd Mumbai.), Estimation kit for Blood urea, Serum creatinine, Serum total protein, albumin and globulin (Bayer Diagnostics Ltd. Mumbai).

1.3.3. Induction of Nephrotoxicity and drug feeding schedule:

All the animals (24 Males) were weighed and randomly divided into four groups comprising of six rats in each. The experimental protocol for Gentamicin induced nephrotoxicity is cited in **Table 1**. The kidney damage was induced by subcutaneous injection of Gentamicin @ 80 mg/kg on 6th day onwards in Groups II, III and IV. Group I and IV were kept as normal (Saline) and toxic control group, respectively. On the other hand, Group II and III were treated with *Sirupeelai kudineer* @ 270.0 mg/kg and *Sirupeelai kudineer* @ 500 mg/kg orally, respectively. The dose of the drug was calculated on the basis of results from acute toxicity studies (1/10th of the maximum tolerated dose).

Blood samples were collected through retro orbital sinus of all the animals on 11th day of experiment. The blood samples were estimated for biochemical parameters such as Blood urea nitrogen, Serum creatinine, Total protein, Albumin and Globulin. After blood collection all the animals were weighed and euthanized under ether anesthesia and the kidneys were collected, weighed and preserved in neutral buffered 10% (V/V) formalin for histopathology. These were processed for paraffin embedding using ethyl alcohol as de-hydrant and xylene as clearing agent. Paraffin sections of kidney, about 4-5 μm thickness, were stained with haematoxylin and eosin. These sections were examined for histopathological changes and the cellular alterations were scored as Nil, +, ++ and +++ for No, Mild, Moderate and Severe damage, respectively.

Table 1 Experimental protocol for Gentamicin model of Nephrotoxicity

Group Number N = 4	Drug Treatment	Route and Dose (in mg / kg bw)	Duration (in days)	Days of withdrawal of Blood and Kidney	Purpose
1	Saline	p.o	1 st to 10 th	11 th	Control
2	Gentamicin + <i>Sirupeelai kudineer</i>	80 mg / kg. s.c 270 mg / kg. p.o	5 th to 10 th 1 st to 10 th	11 th	Protective effect
3	Gentamicin + <i>Sirupeelai kudineer</i>	80 mg / kg. s.c 500 mg / kg. p.o	5 th to 10 th 1 st to 10 th	11 th	Protective effect
4	Gentamicin	80 mg / kg. s.c	1 st – 6 th	7 th	Induce kidney damage

1.3.4. Statistical Analysis:

The data collected were subjected statistical analysis using unpaired t-test (P. S. S. Sundar rao, J. Richard). The statistical significance of difference was taken as $P < 0.05$.

RESULTS AND DISCUSSION

1.4. Biochemical Reports:

The Biochemical analysis of the drug *Sirupeelai* reveals the presence of Minerals with the percentage of Selenium in 0.043%, Manganese in 0.053%, Lead in 0.003%, Copper in 0.002%, Potassium in 2.075% and Calcium.

X-Ray fluorescence studies on the drug *Sirupeelai* reveals the presence of minerals namely Zinc, Iron, Calcium and Potassium.

1.5. Pharmacological Reports:

In the present study the mean Blood urea, Serum creatinine, Total protein, Albumin and Globulin value of each group of rats at the 11th day of the experiment is compared with the values of Nephro-toxic control group. Mean levels of Blood urea, Serum creatinine, Total protein, Albumin and Globulin are presented in **Table 2** and **Table 3**; the representing Charts in **Figure 1, 2 and 3**.

In this study the rats included in Group IV (Nephrotoxic control) showed significant increase in Blood urea level on comparison with the values of Group I ($P < 0.001$). In the group II (*Sirupeelai kudineer* @ 270.0 mg/kg orally for 10 days) there was significant reduction in Blood urea levels as compared to that of Group IV ($P < 0.05$). In the group III (*Sirupeelai kudineer* @ 500.0 mg/kg orally for 10 days) there was significant reduction in Blood urea levels as compared to that of Group IV ($P < 0.02$).

Table 2 Effect of *Sirupeelai Kudineer* in Gentamicin induced Renal damage

Group Number	Percent Change in Body Weight	Blood Urea (mg / dl)	Serum Creatinine (mg / dl)
I	5 \pm 2.24	26.16 \pm 1.44	0.62 \pm 0.03
II	- 8.33 \pm 1.67	65.83 \pm 5.34 ^a	1.25 \pm 0.05
III	4 \pm 1.86	59.67 \pm 5.24 ^b	1.08 \pm 0.04 ^a
IV	5.33 \pm 2.67	119 \pm 20.93 ^c	1.5 \pm 0.15 ^c

Values are mean \pm S.E, Unpaired t – test

^a $P < 0.05$ Vs toxic (Gr IV). ^b $P < 0.02$ Vs toxic (Gr IV).

^c $P < 0.001$ Vs control (Gr I).

On analyzing the Serum creatinine levels, the rats included in group IV (Nephrotoxic control) showed significant increase ($P < 0.001$) on comparison with that of Group I. In the group II (*Sirupeelai kudineer* @ 270.0 mg/kg orally for 10 days) there was reduction in Serum creatinine levels as compared to that of Group IV. But the values are

statistically non significant. In the group III (*Sirupeelai kudineer* @ 500.0 mg/kg orally for 10 days) there was significant reduction in Serum creatinine levels as compared to that of Group IV ($P < 0.05$).

Table 3 Effect of *Sirupeelai kudineer* in serum protein levels

Group number	Total protein	Albumin	Globulin	A / G ratio
I	7.75 ± 0.19	3.1 ± 0.1	4.65 ± 0.22	0.67 ± 0.11
II	6.73 ± 0.19	2.98 ± 0.06	3.81 ± 0.17	0.79 ± 0.03
III	6.85 ± 0.16	3.08 ± 0.13	3.76 ± 0.13	0.82 ± 0.05
IV	8.06 ± 0.37	2.95 ± 0.12	5.45 ± 0.65	0.55 ± 0.03

Values are Mean ± SE.

Figure 1 Effect of *Sirupeelai kudineer* on blood urea level

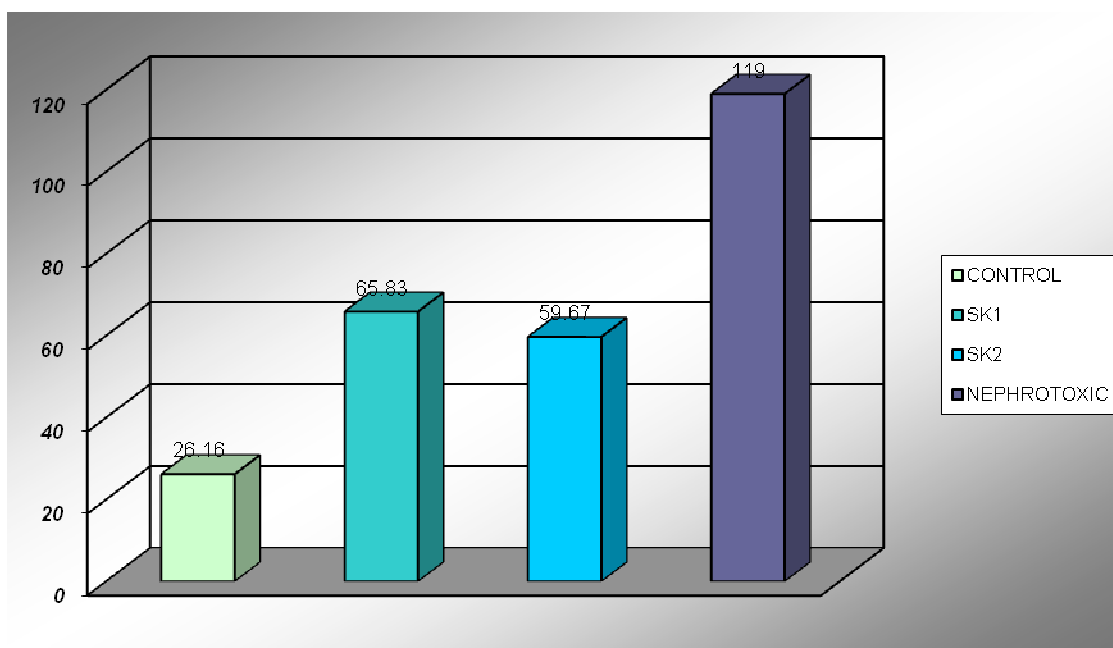
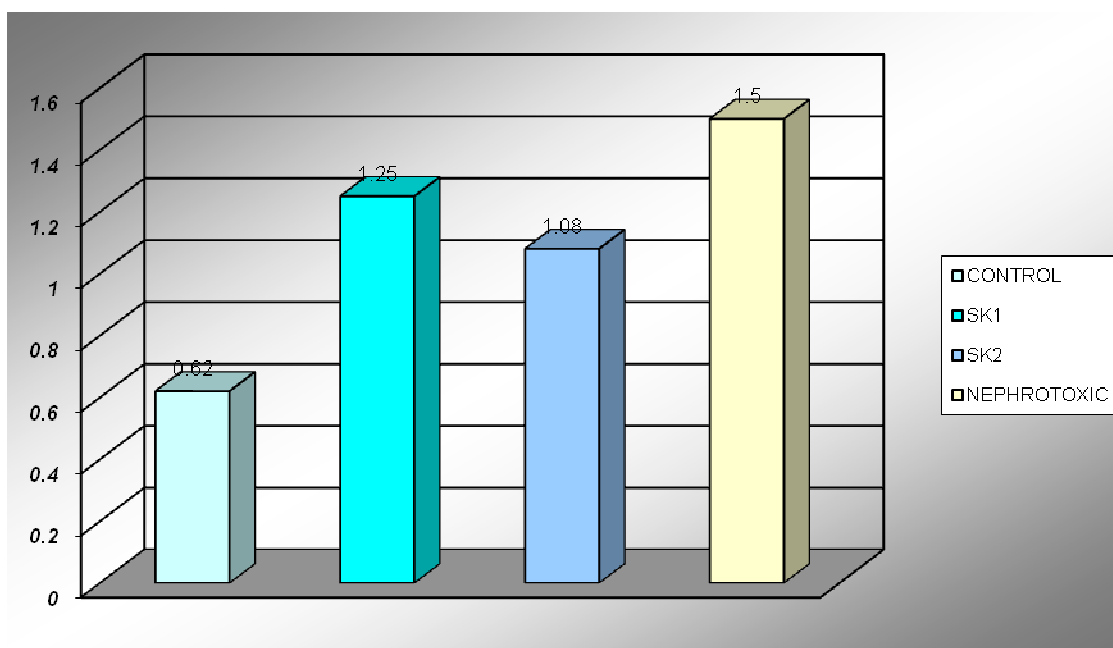
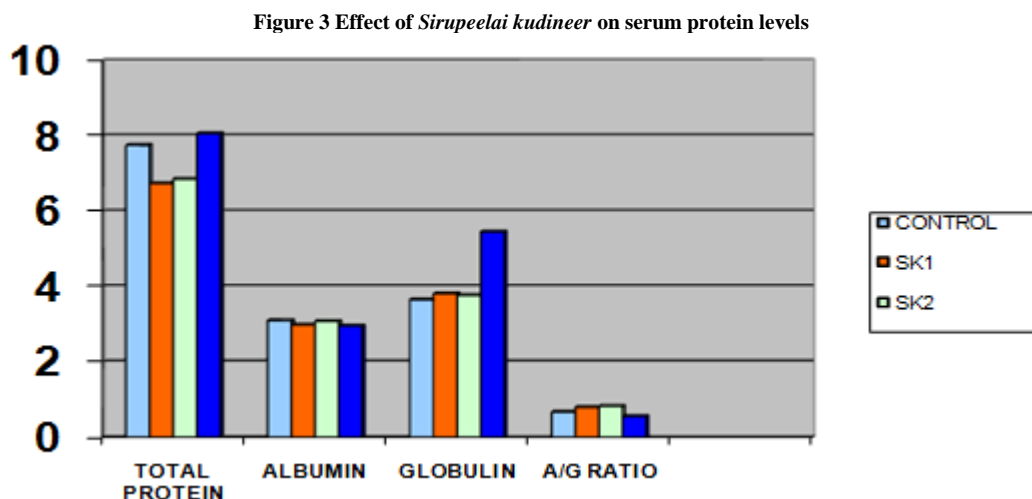


Figure 2 Effect of *Sirupeelai kudineer* on serum creatinine level



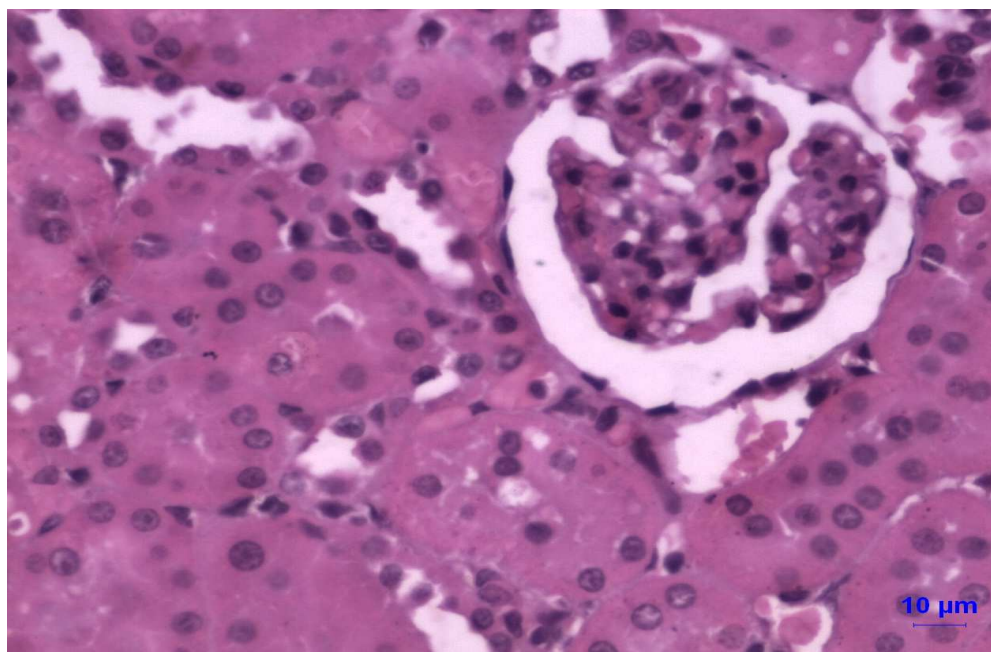


1.6. HISTOPATHOLOGICAL STUDY OF KIDNEY SECTIONS

The present study was primarily designed as inducing Nephrotoxicity in rats using Gentamicin. Focal interstitial nephritis, eosinophilic fluid in the lumen of tubules and tubular epithelial cell necrosis changes were observed in the kidney of rats and no mortality was seen in experimental animals, during the experiment.

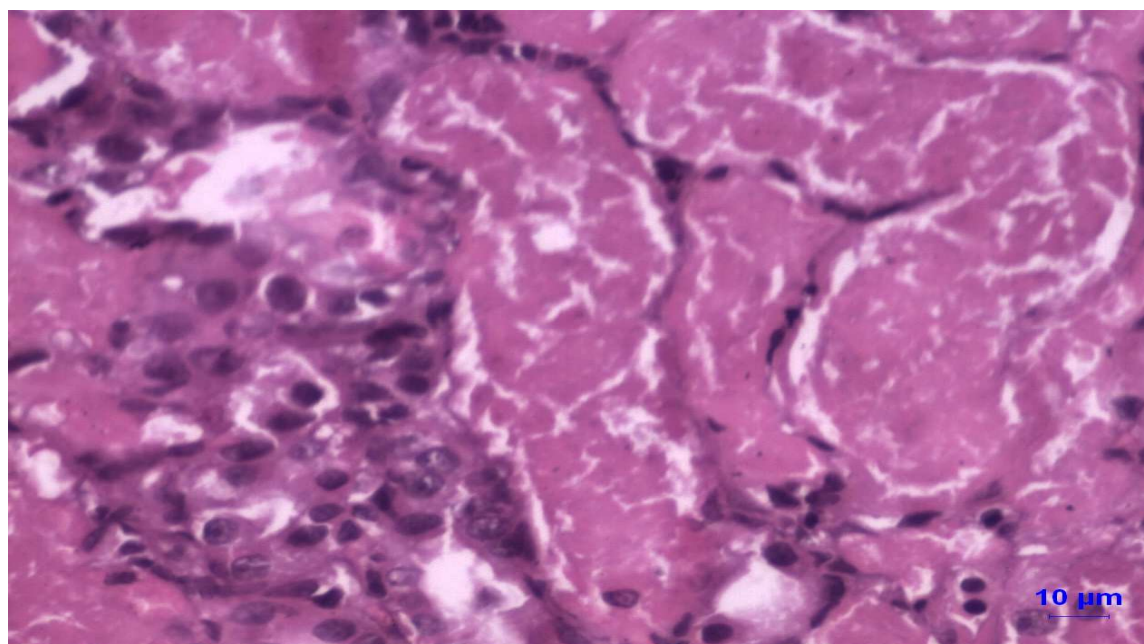
In the sections of kidney obtained on 11th day of the experiment, there was mild degree of damage in group III (+1) followed by Moderate in Group II (+2) and severe damage in Group VI (+3). There were no changes in the sections obtained from Group I, which was normal control. **Figures 4 to Figure 7** illustrate the Photomicrographs of the Sectioned Kidneys in Group I, II, III and IV respectively.

Figure 4 Photomicrograph of rat kidney in Group I (Normal Control) having normal Histological structures of Renal cells

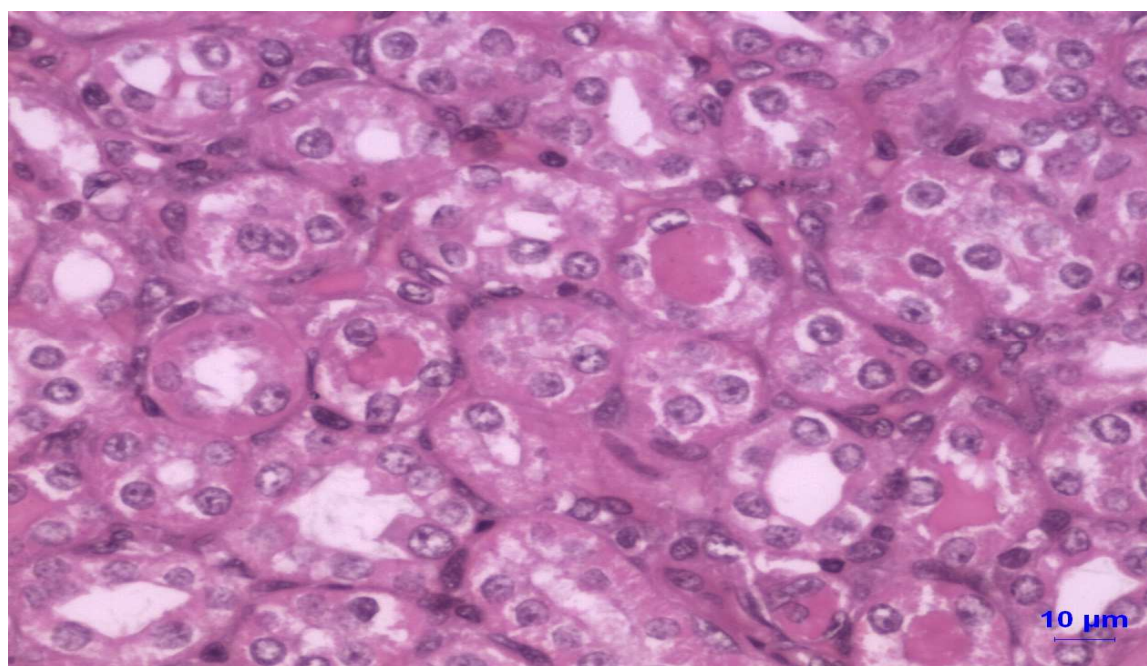


(H & E 320x)

Figure 5 Photomicrograph of rat kidney in Group II, treated with *Sirupeelai kudineer* @ 270.0 mg/kg orally
A. Section showing focal interstitial nephritis

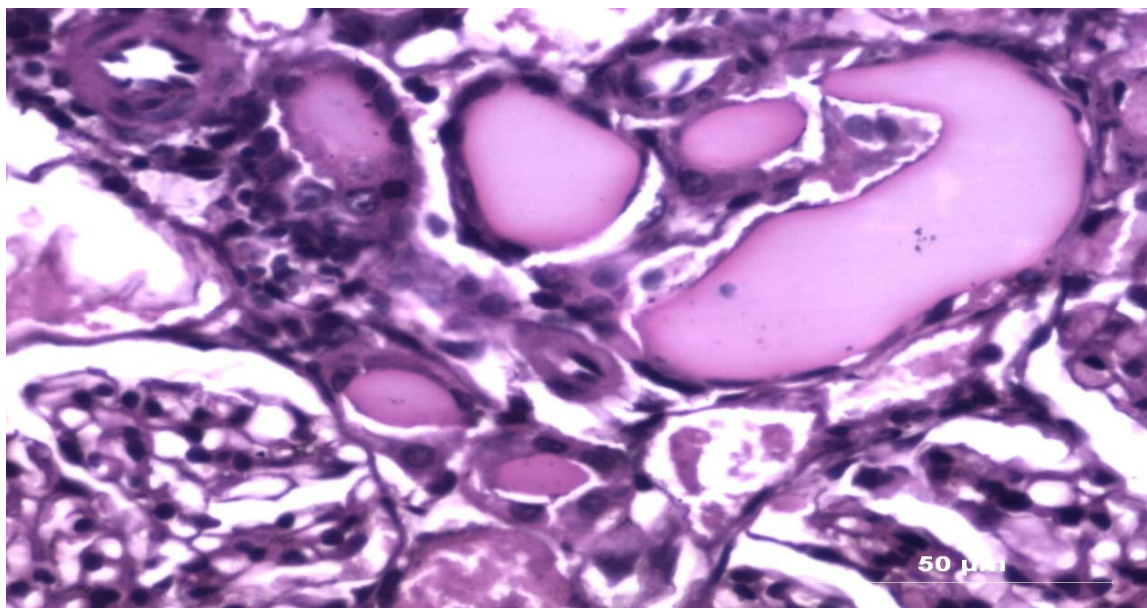


B. Section showing eosinophilic fluid accumulation in the lumen of tubules



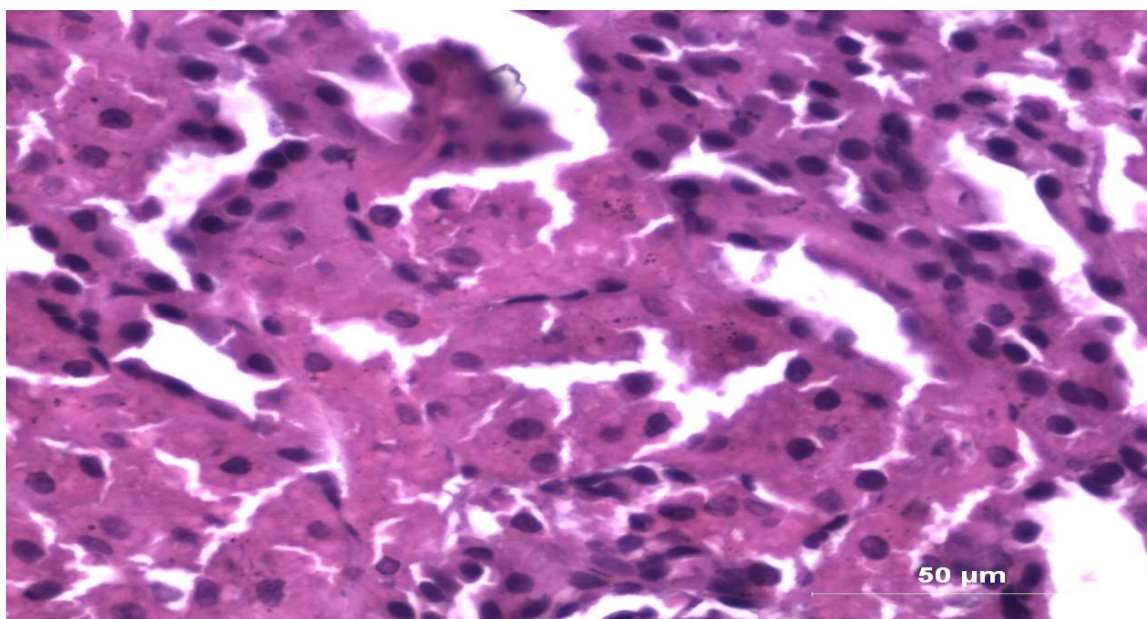
(H & E 320x)

Figure 6 Photomicrograph of rat kidney in Group III, treated with *Sirupeelai kudineer* @ 500 mg/kg orally showing eosinophilic fluid accumulation in the lumen of tubules



(H & E 320x)

Figure 7 Photomicrograph of rat kidney in Group IV (Nephrotoxic Control), treated with Gentamicin @ 80mg/kg, intramuscularly showing tubular epithelial cell necrosis



(H & E 320x)

As per the Literature review, the drug *Sirupeelai* is used as a single drug or in combination with other drugs for the treatment of *Neeradaippu* and other urological disorders. Apart from these it was also indicated for *sobai* (anasarca) and *Raktha pitham* [1] (hypertension), which is complications of *Neeradaippu*.

Review of articles about the plant *Aerva lanata* reveals hepatoprotective, anti oxidant, anti diabetic, anti inflammatory, diuretic and anti microbial activities. Petroleum ether extract of *Aerva lanata* showed a significant reduction in lipid peroxidation in liver microsomes. Its effects on anti oxidant enzymes of liver are also being studied by K G Nevin, P.L Viyammal on 2005.

The present study is being designated to protect the kidney damage induced by Aminoglycoside (AG) like Gentamicin in rat model. AG on intracellular bio-activation produces reactive oxygen species and lipid peroxidation

in kidneys. The results of various studies suggested that treatment of rats with hydroxyl radical scavengers protect against Gentamicin induced renal damage. [8]

The Biochemical analysis of the drug *Sirupeelai* reveals the presence of minerals namely Selenium, Manganese, Lead, Copper, Potassium and Calcium. Wherein Selenium may prevent lipid peroxidation and protects the cells against the free radicals including super oxide; maintain structural integrity of biological membranes. [8]

Manganese is a component of the antioxidant enzyme manganese superoxide dismutase (MnSOD) which can neutralize free radicals and may reduce or even help to prevent some of the damages of organs they cause and inhibits lipid peroxidation. [9] Zinc also comprises the structural role of copper/zinc-superoxide dismutase (Cu/Zn-SOD), it may also have antioxidant activity via its association with the copper-binding protein metallothionein.

Copper, also contributes to the function of very many antioxidants, assisting the "mopping up" of the free radicals that cause cell damage. In general, calcium reduces Amino Glycoside (AG) nephrotoxicity. [10] Potassium also plays a vital role in the preservation of the permeability of cells. Long standing potassium deficiency may cause injury to myocardium and severe renal damage leading to chronic renal diseases. The presence of such minerals in the drug may be supportive or inducing of the antioxidant and free radical scavenging activity.

X-Ray fluorescence studies on the drug *Sirupeelai* reveals the presence of minerals namely Zinc, Iron, Calcium and Potassium. Iron is also essential for the patients of chronic renal damage which plays a vital role in the transport of Oxygen to tissues and participation in cellular oxidation mechanism. [11]

In Pharmacological aspect, Rat is a suitable animal model for studies of AG nephrotoxicity in humans since pharmacokinetics and toxicology of AG are remarkably similar in rats and human. [10] Hence the Nephroprotective activity of the said drug is being evaluated in rat models using Wistar albino rats. The study demonstrates renal damage in toxic groups, evidenced by elevated Blood Urea, Serum Creatinine levels and histopathological features of acute tubular necrosis, the protective groups administered with the decoction of *Sirupeelai* at the dose of 5.4 ml and 10 ml / kg BW along with Gentamicin showed protective effects on renal damage evidenced by reduction in blood urea and serum creatinine levels and histopathological studies.

Basically, most of the synthetic antioxidants like flavanoids, synthetic vitamins and minerals are not working as antioxidants while the natural products containing crude drugs with fibrous products act as anti oxidant and free radical scavengers. [12] In Siddha system of medicine many of the drugs are used in crude forms as natural products, they may act better than synthetic drugs. What the *Siddhars* are doing since years may give proper solution for many chronic ailments.

CONCLUSION

The Pharmacological studies showed that the drug has significant nephroprotective activity at the dose of 5.4 ml and 10 ml / kg BW and no significant adverse effects. It can be concluded that the Nephroprotective activity of the herb *Aerva lanata* may be due to the presence of antioxidants. Further, the Nephroprotective and curative effect of the drug on chronic renal damage has to be studied. Its effect on lipid peroxidation in kidneys and antioxidant enzyme status in kidneys during treatment with *Sirupeelai* is to be evaluated.

Acknowledgement

The Authors sincere thanks submits to Dr. S. Bhoopathy Raj, Head of the Gunapadam department, National Institute of Siddha, Tambaram Sanatorium, Chennai. The Author is more thankful to the Director of Central Research Institute for Siddha, Arumbakkam, Chennai, who has permitted to conduct the pharmacological study in CRIS laboratory. Further, extends the thanks to Dr. Sharad Pawar Department of Pharmacology and Mr. R. Ganesan, Department of Biochemistry in CRIS Chennai.

ABBREVIATIONS

AG	Aminoglycoside
AAL	Aqueous extract of <i>Aerva lanata</i> ()
PF	Partially purified petroleum ether extractable fraction of the whole plant <i>Aerva lanata</i>
PEF	Partially TLC-purified fraction
DLA	Dalton's lymphoma ascites
EA	Ehrlich ascites
AAS	Atomic Absorption Spectrometer
XRF	X-ray fluorescence

REFERENCES

- [1] Dr. K. S. Murugesu Mudhaliar, Gunapadam First Part – Mooligai vaguppu; Directorate of Indian Medicine and Homeopathy. Page 686-687
- [2] Raja Sundararajan; *Pharmacophore* **2014**, Vol. 5 (1), 160-182; Agasthiar Gunavaagam; Directorate of Indian Medicine and Homeopathy, Chennai; Page 218-221.
- [3] *Bogar Nigandu1200*; First Edition, Verse No: 859; Directorate of Indian Medicine and Homeopathy, Chennai.
- [4] T. Vetriseelan, et al, *Journal of Ethnopharmacology* Volume 80, Issues 2–3, May 2002, Pages 103–107; Published by Elsevier Science Ireland Ltd.
- [5] K.G. Nevin et al, *Journal of Environmental Toxicology and Pharmacology*; Volume 20, Issue 3; *Pages 471-47*.
- [6] *Fitoterapia (Fitoterapia)*; **2002**, Vol. 73, Pg. 92-94 (2 ref.), 2003 Vol 74 Pg 578 - 582. ISSN 0367-326X; Elsevier publication.
- [7] Joseph E. pizzorno Jr, Michael T; *Textbook of Natural Medicine*. Volume: 1. pg 442 – 444;
- [8] U. Sathyanarayana; *The Textbook of Biochemistry*; Page 450.
- [9] Robin. S. Goldstein, Constantin Cojocel; *Comprehensive toxicology - aminoglycoside nephrotoxicity*; Volume 7- renal toxicology.
- [10] Davidson's *Principles and Practice of Medicine*, Eighteenth Edition, **1999**; Page 418.
- [11] *Reader's digest February* – **2007**; Page 83-84.