



Effect of Essential Oil of *Rosmarinus officinalis* L. (Rosemary) on the Healing of Cutaneous Lesions in Mice

Jennifer Thayanne Cavalcante de Araujo^{1,2}, Flavia de Oliveira Pantoja^{1,2}, Paula Stefany Ferreira Sá^{1,2}, Núbia Priscila Leite Távora^{1,2}, Andressa Viana Pinheiro³, Thaysa Bastos Mourão Trindade³, Vani Hoyos Figueira Pinto³, Clarissa Silva Lima⁴, Ana Rita Pinheiro Barcessat⁵ and Mayara Tania Pinheiro^{1*}

¹Department of Biological and Health Sciences, Faculty of Pharmaceutical Sciences, General and Analytical Chemistry Laboratory of the Federal University of Amapá, Brazil

²Undergraduate Course of Pharmaceutical Sciences, General and Analytical Chemistry Laboratory of the Federal University of Amapá, Brazil

³Analytical Chemistry Laboratory of the Federal University of Amapá, Brazil

⁴Laboratory of Reproductive Toxicology and Biochemical of the Federal University of Amapá, Brazil

⁵Department of Biological and Health Sciences, Faculty of Nursing, Federal University of Amapá, Brazil

ABSTRACT

The species *Rosmarinus officinalis* L. (Rosemary) is a spice known since antiquity and used both in the food and in a therapeutic area. In popular medicine, Rosemary is used as a general stimulant, antihypertensive, Stomach, antiseptic pulmonary, organic, carminative, choleric, antirheumatic, diuretic, anti-inflammatory, and healing. The essential oil of *R. officinalis* L. Presents antibacterial, cytotoxic, antioxidant, antimutagenic, anti-inflammatory, chemoprotective, immunostimulating, antidiabetogenic and hepatoprotective activity. This work aims to evaluate the effect of *R. officinalis* essential oil as a healing agent in the treatment of skin lesions induced in mice. Thirty animals were used, divided into treatments with a period of 7, 14 and 21 days. Each treatment period consisted of 10 animals, 5 of the Alecrim Group (GA), which received the essential oil of *R. officinalis*, and 5 animals of the Control Group (CG) receiving the 0.9% saline solution. All animals of both groups were treated with 100 µL of oil or saline solution on the lesion. Throughout the treatment period, each lesion was measured and photographed. All animals that were treated with the essential oil of *R. officinalis* obtained satisfactory responses, both visually and statistically. Signifier positive differences ($p < 0.01$) between treated and control groups were observed in different aspects of wound healing process. Reduced inflammation and enhanced wound contraction, re-epithelialization, regeneration of granulation tissue, angiogenesis and collagen deposition were detected in the treated wounds, demonstrated the Therapeutic potential of Rosemary for topical use.

Keywords: Healing; Rosemary; *Rosmarinus officinalis*; Essential oil

INTRODUCTION

The use of medicinal plants can be understood as a practice that goes through millennia, being historically present in the wisdom of common sense, articulating culture and health, since these aspects do not occur in isolation, but inserted in a determined historical context [1]. For centuries, products of plant origin are the basis for treatment of various diseases through the traditional knowledge about the therapeutic properties of a certain plant as a source of active molecules [2]. In the wound healing process, their use does not differ, they are mentioned from prehistory, when plants and plant extracts were used, in the form of cataplasms, in order to staunch hemorrhages and promote healing, many of these plants Ingested, to act in a systemic way [3,4]. The cicatricle process is common to all wounds, regardless of the agent that caused it, is systemic and dynamic and is directly related to the general conditions of the organism [5,6]. Wound healing consists of the perfect and coordinated cascade of cellular, molecular and biochemical events that interact for tissue reconstitution to occur. Carrel described mechanisms of healing in an orderly sequence of events in 1910 [7] and later divided into five

main elements: inflammation, cell proliferation, granulation tissue formation, wound contraction and remodeling [8]. Recently, Clark reclassified this process in three phases, divided into inflammatory phase, proliferation or granulation phase, and remodeling or maturation phase [9-11]. Tissue injury - an initial stimulus for the healing process - places blood elements in contact with collagen and other substances in the extracellular matrix, causing platelet degranulation and activation of the coagulation and complement cascades. This leads to the release of several vasoactive and chemotactic mediators that drive the healing process by attracting inflammatory cells to the wound region [12]. Rosemary (*Rosmarinus officinalis* L.) is a plant belonging to the family Lamiaceae (Labiatae), originating in southern Europe and North Africa [13]. It is also known by the popular names of alecrim-da-horta, alecrim-de jardim, alecrim-de cheiro, alecrim-rosmarinho roris marino (Latin), rosemary (English), romero (Spanish), romarin (French), ramerino (Italian), rosmarin (German). According to reports found in the literature, this plant may present stomach, stimulant, antispasmodic and cicatrizing properties [14]. The used parts of the plant are the flowering leaves and summits from which the essential oil is obtained. It presents astringent, analgesic, antiseptic, antispasmodic, anti-inflammatory, antioxidant, aromatic, digestive, stimulant, tonic and vasodilator functions. It is used in popular medicine as a general stimulant, hypertensive, stomach, pulmonary antiseptic, organic, carminative, cholagogue, choleric, emenagogue, antirheumatic and diuretic [15]. The antimicrobial and antioxidant effects have been frequently demonstrated, however, the clinical effect in the tissue repair process still requires clarification [16,17]. The present study had as objective to evaluate the healing effect of the essential oil obtained from the leaves of *Rosmarinus officinalis* L. on cutaneous lesions induced in mice.

EXPERIMENTAL SECTION

Plant Material

Dried leaves of the species *Rosmarinus officinalis* were obtained from the Flowers and Herbs Pharmaceutical Trade Laboratory - FLORIEN (Distributor of pharmaceutical supplies) located on the Vivente Bellini road, 175-Bairro Conceição - Piracicaba -SP, coming from Turkey, containing botanical authentication as *Rosmarinus officinalis* L.

Extraction of the Essential Oil of *R. officinalis* L

The essential oil was extracted by hydrodistillation in a Clevenger apparatus for 3 hours [18] at the Laboratory of Pharmaceutical Research of the Federal University of Amapá. The oil was then collected (4 g) and stored in a sterile container without the presence of Light at -10°C until the moment of use.

Animals

Thirty Swiss female mice, with an average weight of 45 ± 50 g, were used from the Laboratory of Research in Drugs of the Federal University of Amapá. These were kept in plastic cages, under ambient conditions of temperature and humidity, with free access to potable water and rations for rodents. With light and dark cycle of 12 hours. The animals were divided into two groups of 15 animals: Alecrim Group (AG) (n=15) and Control Group (CG) (n=15). The groups were randomly divided into three subgroups according to the Observation (7, 14 and 21 postoperative days), with 5 animals in each subgroup.

Anesthesia and Operative Procedure

The animals were submitted to anesthesia intraperitoneally, using the combination of anesthetics Ketamine and Xylazine, with a dose of 90 mg/kg in 10 g/100 mL and 5 mg/kg in 2 g/100 mL, respectively. After anesthetized, the animals were placed in the ventral decubitus position and submitted to trichotomy on the dorsum. Two round wounds with 6mm^2 were created on the back of each animal with a metallic surgical punch.

Post-operative

After the surgery, each animal was conditioned in a specific cage according to its due group, and then the first topical application of 100 μL of essential oil was carried out for the Alecrim Group (AG) and 100 μL saline solutions 0.9% for the Control Group (CG). This procedure was repeated every 24 hours during each treatment period. All animals were constantly examined and evaluated macroscopically, observing the presence or absence of secretion, crusts or necrosis. This entire protocol was submitted to the animal research ethics committee and approved under the number 005/2015.

Planigraphy

The lesions were measured every 24 hours, with the aid of a digital caliper. The daily data were recorded on individual files of each animal, in order to calculate the value of the area of the lesion, and then the numerical variation of the cicatrization. The values were calculated day by day for each animal during the proposed period

using the following formula: $R \times r \times \pi = \text{Area}$, where R is the largest radius, r is the smallest radius and π is equal to 3.14.

Statistical Analysis

The data were analyzed using the program GraphPad InStat. The numerical variable, surgical area (cm²), comparing the average was done by the Tukey test. The joint evaluation of the effects of Control group (CG) and Alecrim group (AG), and experimental times (7, 14 and 21), as well as the interaction between them, was done using the two-way ANOVA test. The level of significance used to reject the null hypothesis was 5% ($p < 0.05$).

RESULTS AND DISCUSSION

Clinical Evaluation of Healing Evolution

After seven days of treatment, the most secretive and swollen wounds from the control group (CG) were observed, with a significant absence of granulation tissue and crusts, predominantly hyperemic and without necrosis in any animal (Figure 1A). The Alecrim group (GA) presented secretion in only two wounds and the presence of bright red granulation tissue could be identified from the 3rd day of treatment, being considered a fragile granulation tissue and later a thick granulation tissue (Figure 2A).

For the 14-day subgroup, the Alecrim group continued to show secretion in two animals, but without necrosis in any animal, similar to the Control group. In relation to the presence of granulation tissue, the Alecrim group presented significant growth, and it could be evidenced the reepithelialization of the wound area, with almost complete recovery. This could not be observed in the Control group since the lesions rarely presented the covering by the granulation tissue for the formation of the shell. The lesions presented only dry borders, which at the end of the treatment fell and it was possible to better evaluate the contraction of the lesion, in search of a reepithelialization (Figures 2A and 2B).

At the 21-day experimental time, the Alecrim group maintained the best healing index when compared to the control. All AG animals were characterized as cicatrized, whereas the CG had only one animal with the same clinical evolution.

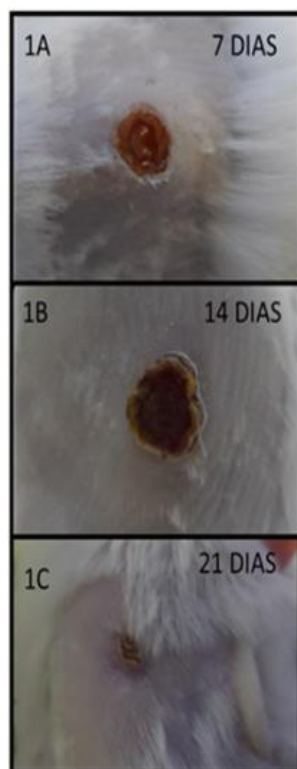


Figure 1: The pictures 1A, 1B, 1 C show, respectively 7, 14 and 21 days of treatment of the control group

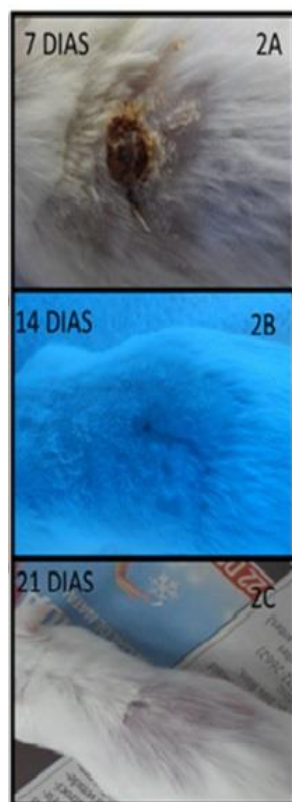


Figure 2: The pictures 2A, 2B, 2C show, respectively 7, 14 and 21 days of treatment of the alecrim group

The presence of a clear aqueous secretion as well as local redness characterize the early process of healing from vasodilatation, functioning as clinical indications of the evolution of the initial cicatricial process. However, it should not last for more than three days, which is the inflammatory phase in uninfected wounds. The control group still presented secretion and hyperemia at the end of seven days evidencing late exit of the inflammatory phase in relation to the Alecrim group. It was possibly due to the known effect of rosemary in the reduction of capillary permeability at the same time Increases the local circulation thus providing greater agility in the process in relation to the control. Assuming that the lesions in question heal by second intention, the presence of the granulation tissue is an important clinical indication of the evolution of the picture, since, after the inflammatory phase, the cicatricial process will occur by the formation of new vessels and fibroblasts. And it will be deposited In the area of the lesion, the early presence of clinically visible granulation tissue in the treated group demonstrates its potential effect on reducing scarring time possibly stimulating angiogenesis, this may be suggested by the amount of neovasal predominant in GA compared to GC seen microscopically (Data not shown).

Reduction of Lesion Area

In relation to the decrease in the lesion area, the subgroups of 7 days, AG and CG, had their means very close and according to the statistic performed between the groups, there was no significant difference (Table 1).

Table 1: Areas of lesions (cm²) of the rosemary and control groups: 7 days postoperative

Alecrim Group (7 Days)		Control Group (7 Days)	
Mice	Areas (cm ²)	Mice	Areas (cm ²)
1	0.2439	1	0.1801
2	0.1427	2	0.3090
3	0.1200	3	0.1163
4	0.2289	4	0.1471
5	0.2361	5	0.2439
Average	0.19432	Average	0.19928

* Represents a statistically significant difference, with p-value <0.05% accepting the alternative hypothesis

The Alecrim group maintained its mean area less than 14 days, showing a significant difference when compared to its control (Table 2).

At 21 days, the lesions of the Alecrim group were all healed, with the exception of animals 3 and 4 of the group, and even not completely healed, obtained very small averages when compared to the Control group (Table 3).

Table 2: Areas of lesions (cm²) of the rosemary and control groups: 14 days postoperative

Alecrim Group (14 Days)		Control Group (14 Days)	
Mice	Areas (cm ²)	Mice	Areas(cm ²)
1	0.1306	1	0.0320
2	0.0116	2	0.0263
3	0.0125	3	0.1306
4	0.0047	4	0.4069
5	0.0034	5	0.1306
Average	0.03256*	Average	0.14528

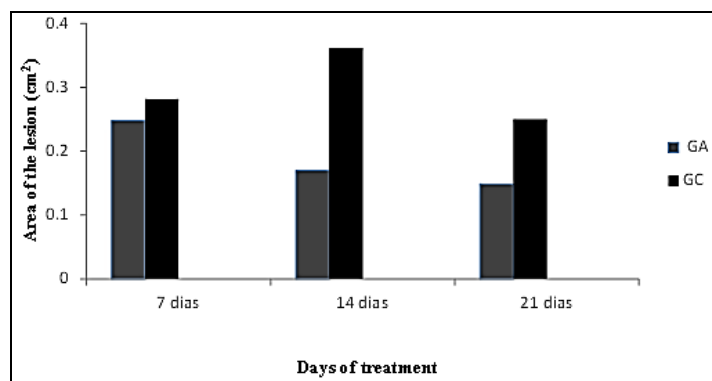
* Represents a statistically significant difference, with p-value <0.5%, accepting the alternative hypothesis

Table 3: Areas of lesions (cm²) of the Alecrim and Control groups: 21 postoperative days

Alecrim Group (21 Days)		Control Group (21 Days)	
Mice	Areas(cm ²)	Mice	Areas(cm ²)
1	0	1	0.0333
2	0	2	0
3	0.0002	3	0.00042
4	0.00028	4	0.00048
5	0	5	0.0228
Average	0.000096**	Average	0.0114

** Represents a statistically significant difference, with p-value <0.001%, accepting the alternative hypothesis

All the areas exposed in Tables 1-3 correspond to the last day of treatment to evaluate the mean of each period. According to the increase in days of treatment, the lesions of the Alecrim group responded satisfactorily, having their area values always smaller than their respective controls. Unlike other works evaluating the cicatrization process, with the use of aroeira [19,20], copaiba [21] and arnica [22]. Using the Tukey test for the comparison of the means of each animal, the value of 0.248 ± 0.023 , GC 7 days 0.282 ± 0.015 , GA 14 days 0.170 ± 0.029 , GC 14 days 0.362 ± 0.058 , GA 21 days 0.149 ± 0.021 and GC 21 days 0.254 ± 0.029 being mean and standard error respectively (Figure 3).

Figure 3: Graph showing the decrease of the area corresponding to the treatment period

Histopathological Description

The histological sections revealed in the treated group, an evident formation of stratified squamous epithelium, still without keratin, in the underlying conjunctiva tissue of exuberant granulation, which exhibited multiple capillaries and young fibroblasts, the same could not be evidenced in the Control group. At 14 days the treated group exhibited complete epithelial formation with deposition of collagen fiber bundles in the underlying conjunctiva with little vascularization, the control group presented a similar pattern but with a more cellular matrix evidencing a younger collagen and a larger number of blood vessels. At 21 days, both groups were compatible with normality, presenting dermal attachment in the epithelium as well as a matrix formed by collagen fibers without cellularisation.

CONCLUSION

As shown in the results of healing evolution and numerical variation of the area, it can be stated that the essential oil of *R. officinalis* (Alecrim) has therapeutic activity in the topical application, showing favoritism of reepithelialization, since all animals that Received better cicatricial responses, with significant results mainly in the subgroups of 14 and 21 days.

REFERENCES

- [1] NAT Alvim. *Revista Latino-Americana de Enfermagem*. **2006**, 14(3), 316-323.
- [2] ACB Carvalho; D Silveira. *Brasília Médica*. **2010**, 48(2), 219-237.
- [3] DM Silva; KR Mocelin. *Nursing*. **2007**, 9(105), 8188.
- [4] MA Piriz; CAB Lima; VMR Jardim; MK Mesquita; ADZ Souza; RM Eck. *Rev Bras Pl Med*. **2014**, 16(3), 628-636.
- [5] G Broughton; JE Janis; CE Attinger. *Plast Reconstr Surg* **2006**, 117(7), 1e-S-32e-S.
- [6] ACB Carvalho; D Silveira. *Brasília Médica*. **2010**, 48(2), 219-237.
- [7] A Carrel. *JAMA*. **1910**, 55, 2148.
- [8] D Orgill; RH Demling. *Crit Care Med*. **1988**, 16(9), 899-908.
- [9] RAF Clark Wound repair. In: Kumar, Robbins, Cotran: *Pathologic Basis of Disease*, **2005**. 7th edition, Ed. Saunders, 112.
- [10] DM Silva; KR Mocelin. *Nursing (São Paulo)*, **2007**, 9(105), 8188.
- [11] CA Balbino; LM Pereira; R Curi. *Brazilian J Pharm Sci*. **2005**, 41(1), 27-51.
- [12] MB Witte; A Barbul. *Surg Clin North Am*. **1997**, 77(3), 509-528.
- [13] ER Martins, DM Castro; DC Castellani; JE Dias. *Plantas medicinais*. 2nd edition. Viçosa, MG: UFV, 1998. 220.
- [14] A May; E Suguino; AN Martins; LES Barata; MQ Pinheiro. *Rev Bras Pl Med*. **2010**, 12(2). 195-200.
- [15] JCT Carvalho; CCJ Almança. *Editora Atheneu*. **2003**, 166.
- [16] T Bakirel, U Bakirel, OU Keleş, SG Ulgen, H Yardibi. *J Ethnopharmacol*. **2008**, 116 (1), 64-73.
- [17] Y Zaouali; T Bouzaine; M Boussaid. *Food Chem Toxicol*. **2010**, 48(11), 3144-3152.
- [18] *Farmacopéia brasileira*. 4th edition. parte II. **2000**, São Paulo: Atheneu.
- [19] MLCB Neto; JMR Filho; O Malafaia; MAO Filho; NG Czezko; S Aoki; R Cunha; VR Fonseca; HM Teixeira; LR.F Aguiar. *Acta Cirúrgica Brasileira*. **2006**. 21, 17-22.
- [20] NMB Brito, Aspectos morfológicos e morfométricos da cicatrização de feridas cutâneas abertas em ratos tratados com óleo de copaíba. [Dissertação]. São Paulo: Programa de Pós-graduação em Técnica Operatória e Cirurgia Experimental, Escola Paulista de Medicina, Universidade de São Paulo **1996**.
- [21] LTGS Miranda. Uso da tintura de arnica em feridas cutâneas abertas em ratos. [Dissertação]. São Paulo: Programa de Pós-graduação em Técnica Operatória e Cirurgia Experimental, Escola Paulista de Medicina. Universidade Federal de São Paulo, **2001**.
- [22] DR Knighton; I Silver; TK Hunt. *Surgery*. **1981**, 90, 262-270.