



ISSN No: 0975-7384  
CODEN(USA): JCPRC5

*J. Chem. Pharm. Res.*, 2011, 3(2):566-575

## Chemical and pharmacological evaluation of aqueous extract of seeds of *Cassia occidentalis*.

A. V. S. Sastry<sup>1</sup>, V. Girija Sastry<sup>\*2</sup>, B. Appalanaidu<sup>2</sup>, K. Srinivas<sup>3</sup> and A. Annapurna<sup>2</sup>

<sup>1</sup>M.R.College of Pharmacy, Vizianagaram (A.P) India.

<sup>2</sup>Andhra University College of Pharmaceutical Sciences, Visakhapatnam, (A.P), India

<sup>3</sup>Vasavi College of Pharmaceutical Sciences, Tadepalligudem, (A.P) India

### ABSTRACT

*Cassia occidentalis* L. (Leguminacea), commonly known as 'Coffee Senna', is used in Unani medicine for liver ailments and is an important ingredient of several polyherbal formulations marketed for liver diseases. The aqueous extract was chemically examined and pharmacologically screened for Hepatoprotective activity. The structure of the new compound isolated from the extract and elucidated by using Modern spectral and chemical techniques. And was found to be an anthraquinone glycoside. The hepatoprotective effect of aqueous extract of seeds of *Cassia occidentalis* was studied on rat liver damage induced by paracetamol and by monitoring SGPT, SGOT, alkaline phosphate, total bilirubin, and histopathological alterations. The extract of seeds of plant produced significant hepatoprotection.

**Key words:-** Paracetamol, *Cassia occidentalis*, liver enzymes, Hepatoprotective, Silymarin.

### INTRODUCTION

The traditional preparations comprise medicinal plants, mineral and organic matter. Herbal drugs constitute only those traditional medicines which primarily use medicinal plant preparation for therapy<sup>1</sup>. Ayurvedic medicine is essentially promotive and preventive in therapeutic approach. Many Ayurvedic medicines are used for treating liver disorders. Thus search for crude drugs of plant origin has become a central focus of study of hepatoprotection<sup>2</sup> and its chemical evaluation. *Cassia occidentalis* is a medicinal plant belongs to *Leguminosae* family commonly known as 'coffee senna'. The parts used are roots, leaves, and seeds.

It is used for fever, menstrual problems, tuberculosis, as diuretic for anaemia, liver complaints and as a tonic for general weakness and illness<sup>3</sup>.

Several active constituents have been isolated like anthraquinones<sup>4</sup>, flavonoids<sup>5</sup>, phytosterols<sup>6</sup> and polysaccharides<sup>7</sup> and they were reported to have hepatoprotective activity.

In view of the above, the present study was carried out with the aim of chemical examination and pharmacologically evaluating hepatoprotective properties of the aqueous seed extract of *Cassia occidentalis* in experimental rat model of liver injury induced by paracetamol.

## EXPERIMENTAL SECTION

**Plant extract:-** The finely powdered (25g) aqueous extract of the plant procured from Laila Impex, Vijayawada, Andhra Pradesh.

**Animals:-** Albino rats (Wistar strain) and albino mice (Swiss strain) used in the present studies were procured from the Ghosh enterprises, Kolkata. All animals were kept under standard laboratory conditions and fed on a standard diet supplied by Rayans Biotechnologies Pvt. Ltd, Hyderabad. The study was approved by Institutional animal ethical committee.

**Extraction and isolation:-** The finely powdered (20g) aqueous extract of the seeds was extracted with methanol by using Soxhlet apparatus. After evaporation of the solvent under reduced pressure 6g of crude extract was obtained. The resulting residue was dissolved in methanol and adsorbed on the 15g of silica gel (100-200 mesh). It was subjected to gradient column chromatography by hexane, ethyl acetate, methanol in increasing polarity. The fraction were collected and monitored on TLC. Upon purification of the collected fraction a novel bis-anthraquinone derivative was obtained along with  $\beta$ -sitosterol. Bis-anthraquinone derivative was obtained at 3% ethyl acetate in hexane fraction. The structure was established by the interpretation of the spectral data (<sup>1</sup>H NMR, <sup>13</sup>C NMR, IR and Mass).

### Acute toxicity studies:-

Albino mice (Swiss strain) were divided into five groups six in each group. One group was set as control group and remaining four groups received (800, 1000, 2000 and 3000 mg/kg b.w.) of the extract orally. The mice were observed continuously for 1hr for any gross behavioural changes and death, if any, intermittently for the next 6 hrs and then again for 24 hrs after dosing. There were no changes in normal behaviour pattern and no signs and symptoms of toxicity and mortality were observed.

**Paracetamol induced hepatotoxicity:-** The rats were divided into six groups I-VI, each group consisting of six rats. The rats in group-I served as vehicle control. Liver toxicity was induced in rats by administering paracetamol orally in a 1% CMC at a dose of 2g/kg body weight for three days in all the groups except control (group-I).

Group-II served as paracetamol control.

Group -III received silymarin (25mg/kg, b.w) for seven days.

Group-IV-VI received aqueous extract (100, 200 and 400mg/kg, b.w) for seven days. All samples were administered orally.

### Biochemical and histopathological parameters:-

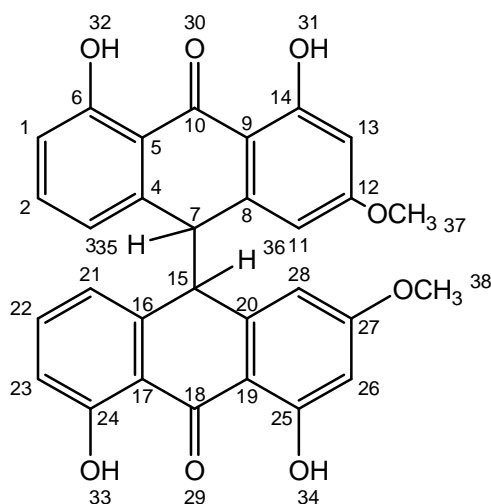
Blood samples of the rats were withdrawn on 1<sup>st</sup>, 4<sup>th</sup> and 10<sup>th</sup> day from the retro-orbital plexus under mild anaesthesia. The blood and serum were separated by centrifugation and used for estimation of biochemical parameters that is SGOT, SGPT, ALP and bilirubin (total).

**Statistical analysis:-** All the results were expressed as mean  $\pm$  SEM. The significance of difference between mean values for the various groups was tested by using one way analysis of variance (ANOVA). The level of significance was  $P < 0.05$ .

**Histology:-** The liver tissue was excised from the animals, washed with normal saline to remove blood, fixed in 10% buffered neutral formalin for 12 hours and processed for paraffin embedding. Section of 5  $\mu$ m thickness was cut using rotary microtome. The sections were processed and passed through graded alcohol series, stained with haematoxylin and eosin<sup>8</sup>, cleaned in xylene and cover slipped in DPX. Histological examination was done under 10 X magnification using Trinocular Research zeiss Microscope (Gottingen, Germany).

## RESULTS

The new compound which was obtained as yellow needles, m.p 325° C. The compound was analysed for  $C_{30}H_{22}O_8$  supported by the molecular ion  $m/z$  510 in its mass spectrum. It gave positive borntragers test for anthraquinone glycosides. Its IR spectrum showed bands at 3426  $cm^{-1}$  (OH) and a band at 1628 for anthraquinone moiety. Its  $^1H$  NMR spectrum exhibited signals at  $\delta$  3.25 (6H, s, 2  $OCH_3$ ) exhibited signals for two aromatic methoxy and signals at  $\delta$  12.308 and  $\delta$  12.110 for four phenolic hydrogens. In the above aromatic region showed signals which on analysis accounting for two aromatic rings with ABC system and two aromatic rings meta coupled protons. The signal at  $\delta$  2.452 accounted for the two protons of dihydro anthraquinonoid ring. The structure of the new compound was closed to arabinol isolated from the whole plant of *Cassia occidentalis*. The difference between the two compounds is that the new bis-anthraquinone has two methoxys instead of two methyls present in arabinol.



4,4',5,5'-TETRAHYDROXY-2,2'-METHOXY-9,9'- BISANTHRAQUINONE

**Acute toxicity studies:-** The extract was found to be safe for further biological studies as no lethal effect was observed even at 3000 mg/kg bw.

**Serum enzymes:-** In the present study, the hepatic damage produced by paracetamol is evident by increasing enzyme levels in serum. Treatment of rats with plant extract for 7 days after paracetamol administration resulted in a significant percent protection against paracetamol induced elevation levels of SGOT, SGPT, ALP and total Bilirubin (Table-1).

**Histological examination:-** The hepatoprotective effect of the test drug was further confirmed by histopathological examinations of the liver sections of the control untreated group (group-I), paracetamol treated group-II and different doses of *Cassia occidentalis* extract + paracetamol treated groups IV-VI, and group-III treated with paracetamol + silymarin. The liver sections of paracetamol treated rats (Figure-II) showed centrilobular necrosis. Treatment with standard silymarin (Figure-III) and different groups of *Cassia occidentalis* (Figure IV-VI), there was less centrilobular changes and hepatocytes showing regeneration activity.

## DISCUSSION

PCM, a well known compound for producing chemical hepatic injury in mice has been used as an experimental model to test the potential hepatoprotective activity by several investigators. Presently it is hypothesized that herbal drugs inhibit the CYP2E1 enzyme activity in hepatic microsomes *in vivo* and *in vitro* and give protection against hepatotoxicity induced by PCM, CCl<sub>4</sub> and nitrosoamines<sup>8</sup>.

PCM treatment significantly increased the serum enzyme levels, namely ALT, AST and ALP indicating chemical induced hepatocellular toxicity. Serum levels of these enzymes are very sensitive markers employed in the diagnosis of liver diseases. When the hepatocellular plasma membrane is damaged, the enzymes normally present in the cytosol are released into the stream. This can be quantified to assess the type and extent of liver injury<sup>9</sup>. ALP is excreted normally via bile by the liver. The liver injury due to toxins can result in defective excretion of bile by hepatocytes which are reflected as their increased levels in serum<sup>10</sup>. Treatment with aqueous extract of *Cassia occidentalis* restored the liver enzyme parameters showing a dose dependent effect. The reduction of liver enzyme parameter, ALT was significant and showed as a specific marker of liver injury due to toxic drugs, alcohol and virus<sup>11</sup>. The protective effect may be the result of stabilization of plasma membrane therapy preventing the structural integrity of cells as well as the repair of hepatic tissue damage caused by PCM<sup>12</sup>.

The herbal drugs or polyherbal combinations are traditionally used in the treatment of liver diseases caused by viral hepatitis, alcohol, toxic drugs and plant toxins. Silymarin from *Andrographis paniculata*, curcumin from *Curcuma longa*, picroside and kutkoside from *Picrorrhiza kurroa*, phyllanthin and hypophyllanthin from *Phyllanthus niruri*, glycyrrhizin from *Glycyrrhiza glabra* are traditionally used in the treatment of liver diseases and represent the phytochemical constituents and have been studied for their chemical and biological profile and clinical efficacy<sup>13</sup>. These show hepatoprotection due to antioxidant effects like immunomodulatory, antiviral; anti-inflammatory, antifibrotic, membrane stabilising and antiprotozoal activities are also documented<sup>14-17</sup>.

## CONCLUSION

The result of the present study demonstrates that the aqueous seed extract of *Cassia occidentalis* has potent hepatoprotective activity against paracetamol induced liver damage in rats. The hepatoprotective activity of the above extract was also found to be dose dependent. As few anthraquinones isolated from *Cassia tora*<sup>18</sup> and *ventilago leiocarpa*<sup>19</sup> are reported to possess hepatoprotective activity, it is like that the anthraquinones<sup>20,21</sup> and flavonoids<sup>22,23</sup> present in *Cassia occidentalis* may be responsible for hepatoprotective activity. Further the new bis anthraquinone derivative which was isolated are of very low yield (30mg) we were unable to conduct the activity for it.

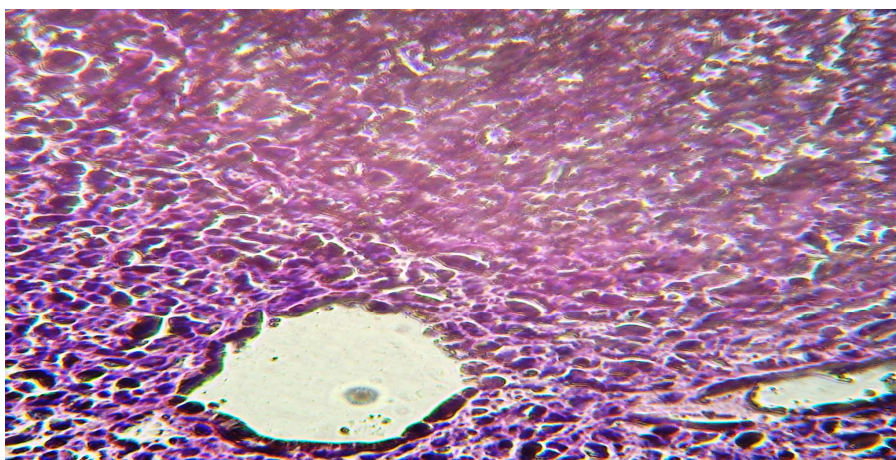
**Table-1: Effect of aqueous extract of seeds of *C. occidentalis* on serum parameters in paracetamol induced (2 g/kg, b.w) hepatic damage in rats.**

Groups	SGOT (IU/L)	SGPT (IU/L)	ALP (IU/L)	BILURUBIN (mg/dl)
Control	130±6.54*	31±5.29*	82±7.82*	0.61±1.08*
Paracetamol standard	222.5±11.12***	55.75±7.85***	133±12.83***	2.39±1.16*
100mg/kg extract	208.3±10.17***	55.33±9.49***	167±9.86***	1.2±0.12*
200mg/kg extract	180±7.93**	46.67±7.05**	137±7.46***	0.83±0.23*
400mg/kg extract	166.7±17.07*	41.3±4.63*	122±12.13***	0.5±0.17*

The data are represented as mean  $\pm$  S.E.M of six animals in each groups. Students *t* test is used for statistical analysis of blood serum parameters. The symbols \* represent the value were  $P < 0.05$  consider to be significant.

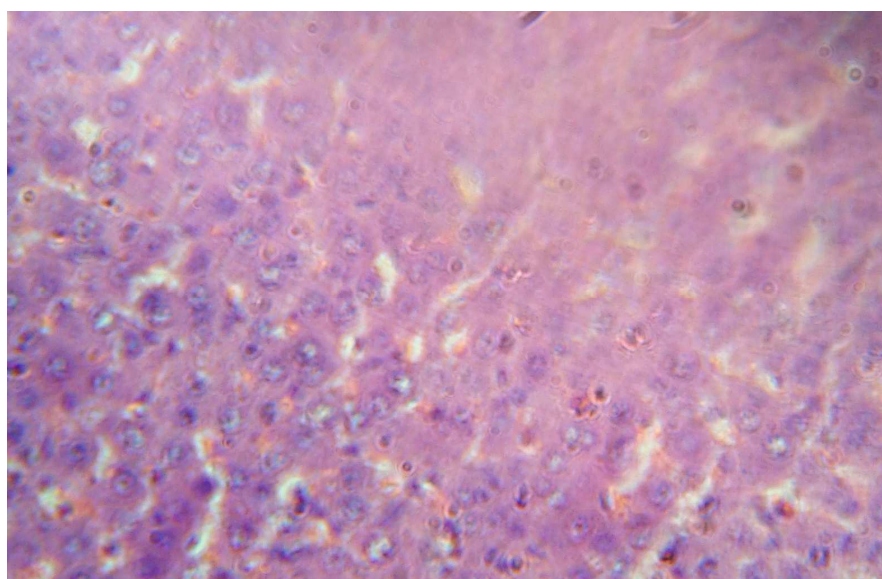
The symbols \*\* represent the value were  $P < 0.01$  consider to be significant.

#### SECTION OF LIVER CONTROL GROUP



**Fig 1: The parenchymatous tissue showing the regenerative changes by emptying of cytoplasm of Hepatocytes and nucleus was centrally located.**

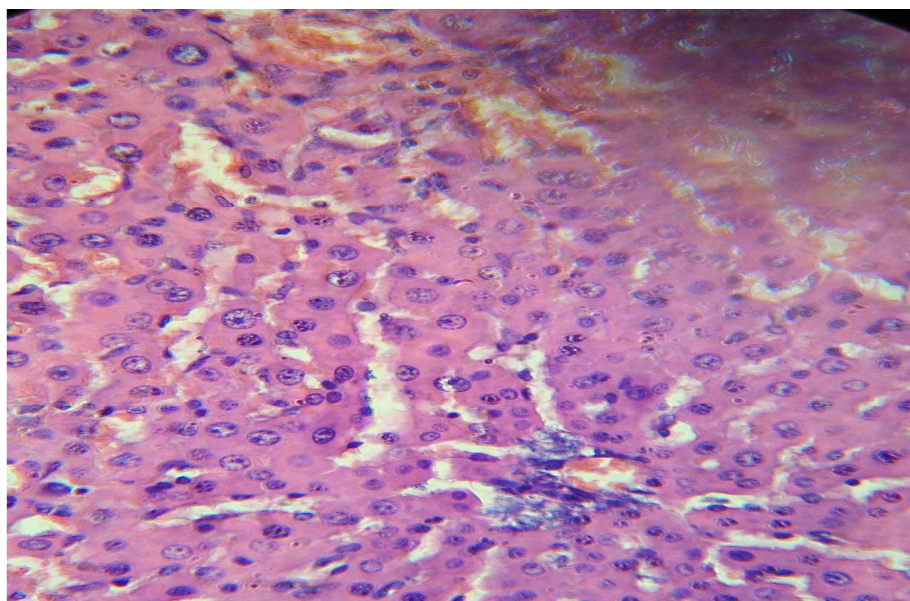
#### SECTION OF PARACETAMOL TREATED GROUP LIVER



**Fig 2: Liver showing mild congestion, increased space of canaliculi moderate vacuolation and foci of necrosis**

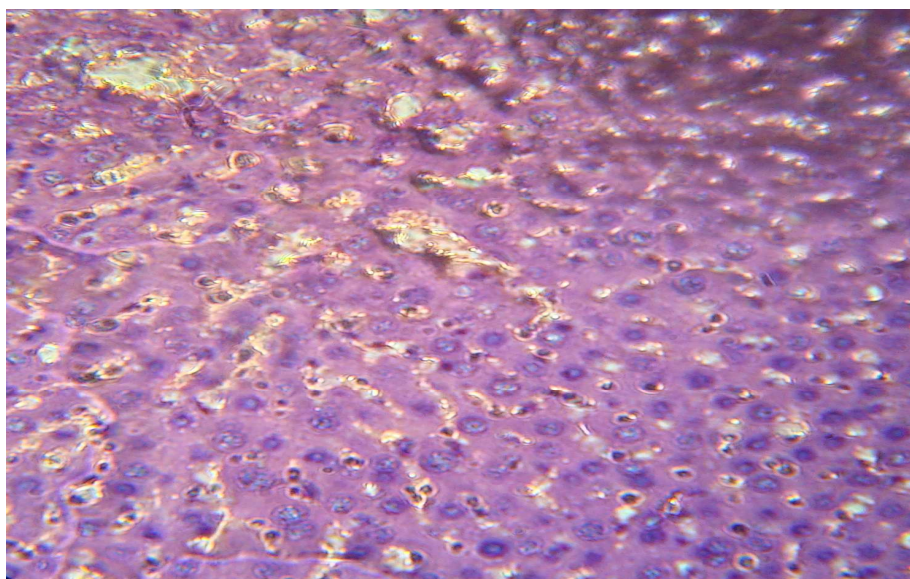


**SECTION OF PARACETAMOL + PLANT EXTRACT (100mg/kg) TREATED GROUP LIVER**



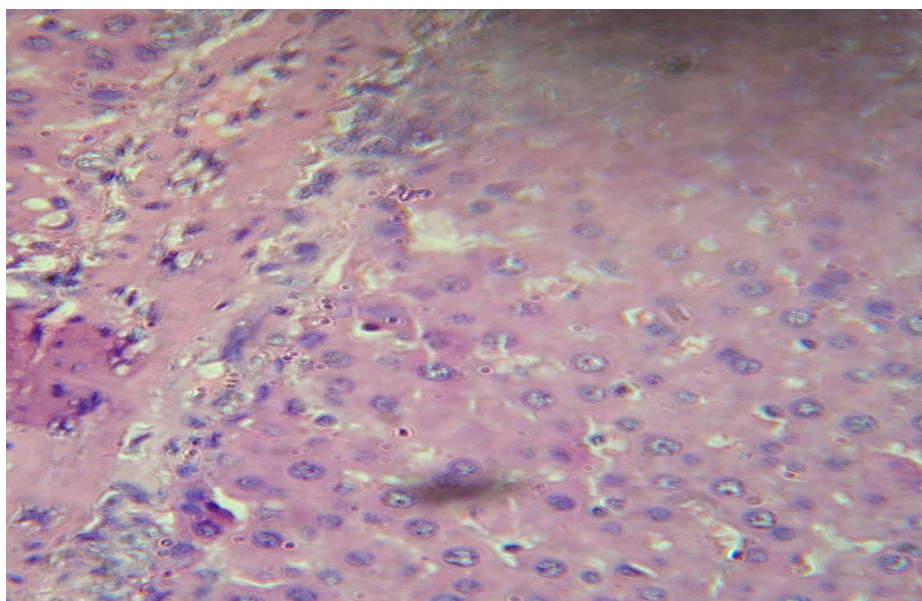
**Fig 3: Hepatic parenchyma revealing a large area of necrosis and serve degenerative changes. Normal space of canaliculi was observed.**

**SECTION OF PARACETAMOL + PLANT EXTRACT (200mg/kg) TREATED GROUP LIVER**



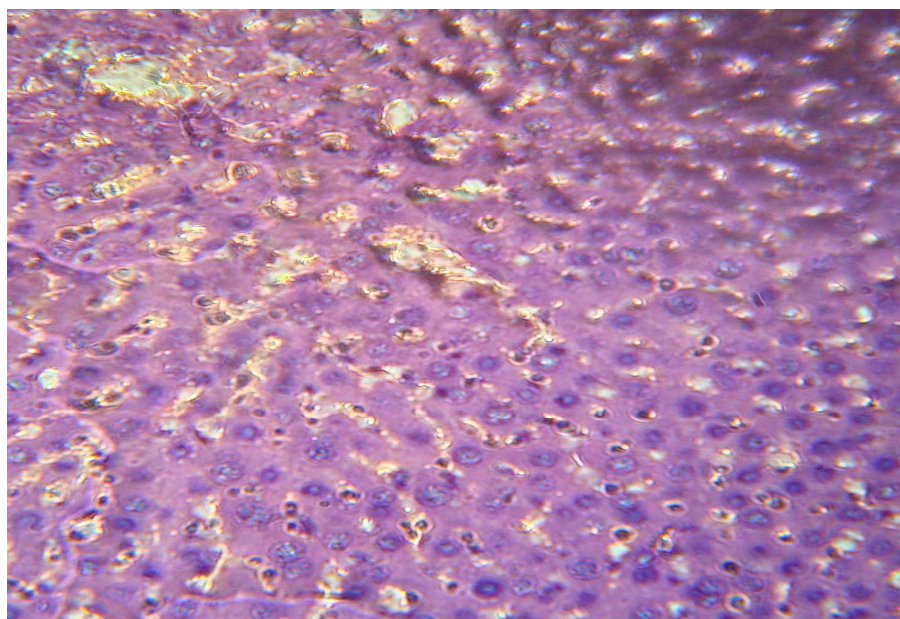
**Fig 4: Hepatic parenchyma revealing a large area of necrosis and serve degenerative changes. Normal space of canaliculi was observed.**

**SECTION OF PARACETAMOL + PLANT EXTRACT (400mg/kg) TREATED GROUP LIVER**

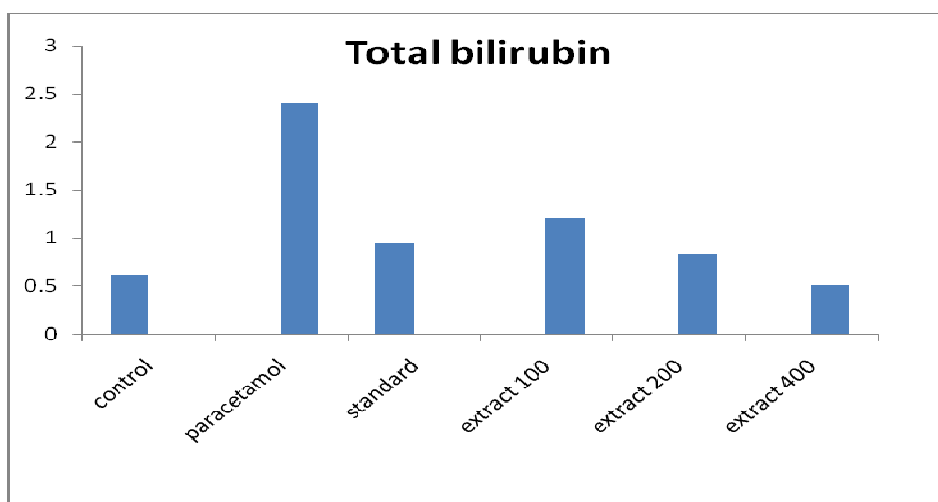
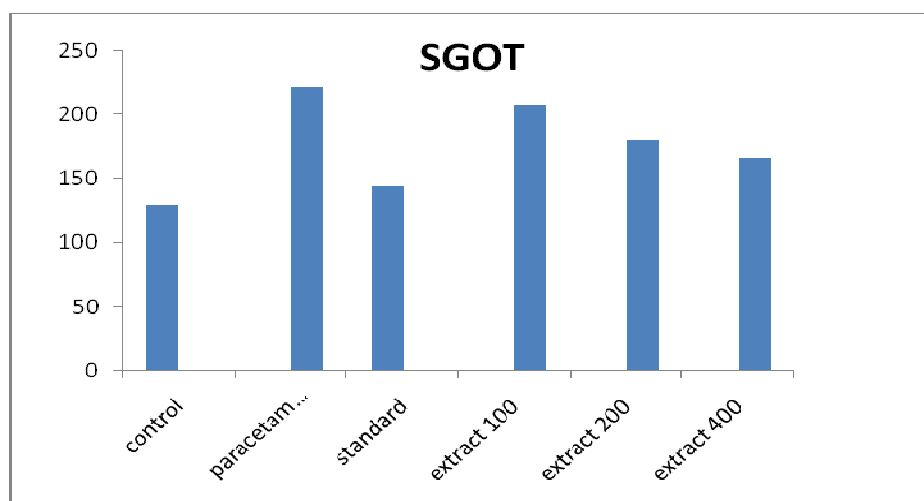
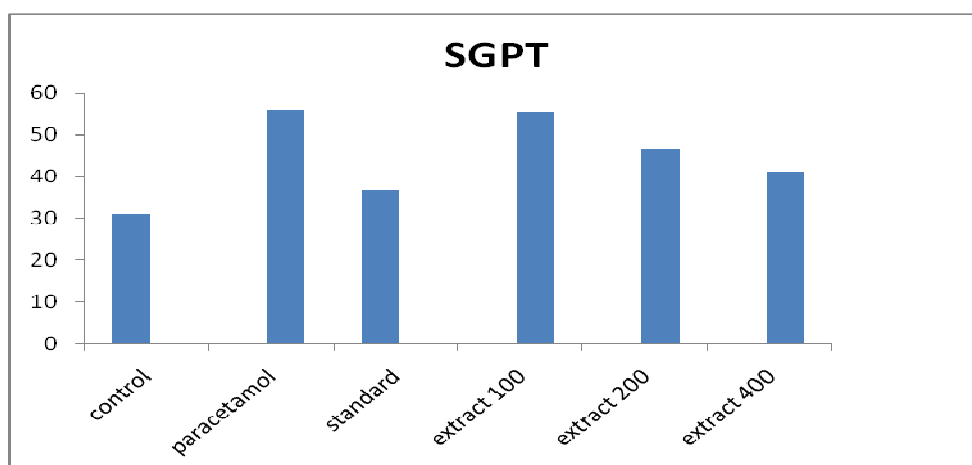


**Fig 5: Hepatocytes were regenerative and showed a milder degree of vacuolation but prominent nuclei, indicating returning to normalcy.**

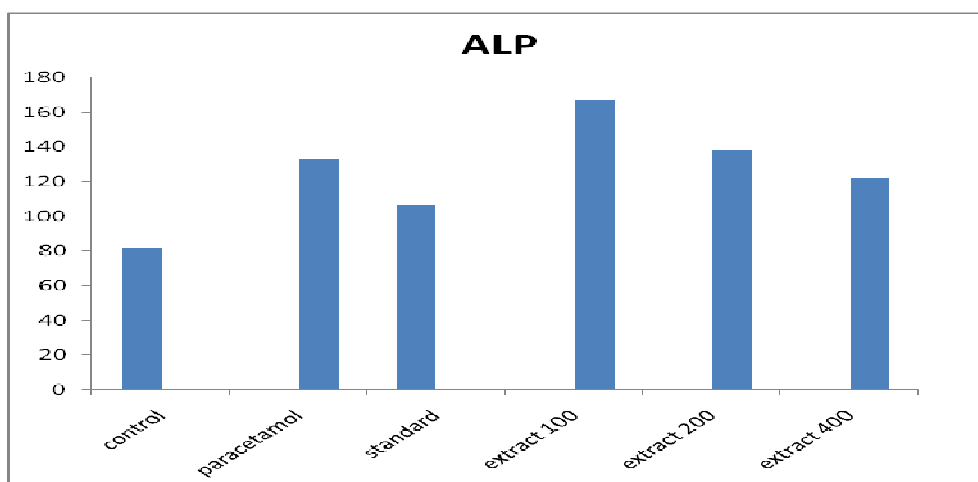
**SECTION OF PARACETAMOL + STANDARD TREATED GROUP LIVER**



**Fig 6: The sheets of hepatocytes were positioned in typical radiation pattern. Hepatocytes were individually demarked with canaliculi space.**

**Graph 1. The effect of various groups on Bio-chemical parameter, such as Bilirubin in Rat serum****Graph 2. The effect of various groups on Bio-chemical parameter, such as SGOT in Rat serum****Graph 3. The effect of various groups on Bio-chemical parameter, such as SGPT in Rat serum**



**Graph 4. The effect of various groups on Bio-chemical parameter, such as ALP in Rat serum**

### Acknowledgements

We wish to thank University college of sciences, Andhra University, Visakhapatnam, for funding this research work.

### REFERENCES

- [1] N.P. Hota, M.M. Pathi. **2003**, Typical uses of certain common and uncommon plants. *Ancient science of life*, 1-6.
- [2] M.R. Ven kumar, M.S. Latha. **2002**, *Ind. J. Clin. Biochem*, 17-2, 80-7.
- [3] K.R. Krithikar, B.D. Basu : **1999**, *Cassia occidentalis* Indian medicinal plants II edition, 86.
- [4] R. Anton, P. Duquenois., **1968**. *Ann Pharm. Francaises* 26 (11), 673-680.
- [5] R.D. Tiwari and J. Singh., **1977**. *Phytochemistry* 16 (7), 1107-1108.
- [6] J. Lal., P.C. Gupta, **1973 a**. *Phytochemistry* 12 (5), 1186.
- [7] D.S. Gupta., S. Mukharjee., **1973 a**. *Indian J. Chem* 11(5), 505-506.
- [8] Y.P. Hwang, C.Y. Choi, Y.C. Chung, S.S. Jeon, H.G. Jeong. **2007**, *Arch Pharm Res*, 30: 1309-17.
- [9] R. Sallie, J.M. Tredger, R. Williams. **1991**, *Biopharm Drug Dispos.* 12: 251-9.
- [10] M.G. Rajesh, M.S. Latha. **2004**. *J Ethnopharmacol.*, 91: 99-104.
- [11] S. Sherlock, J. Dooley. **2002**. *Drugs and the liver*. In: *Disease of liver and Biliary system*. 11 ed. Oxford : Blackwell Scientific publications., p. 322-356.
- [12] L. Pari, P. Murugan. **2004**.. *Pharmacol Res*, 49; 481-6.
- [13] A.S. Negi, J.K. Kumar, S. Luqman, K. Shanker, M.M. Gupta, S.P. Khanuja. **2007**. *Med Res Rev.*, 28: 746-772.
- [14] I.B. Koul, A. Kapil. **1994**. *Indian J Phamacol*, 26; 296-300.
- [15] Y. Fu, S. Zheng, J. Lin, J. Ryerse, A. Chen. **2008**. *Mol Pharmacol*, 73; 399-409.
- [16] M.S. Shin, E.H. Kang, Lee YI. **2005**. *Antiviral Res*, 67; 163-8.
- [17] E.H. Kang, T.Y. Kown, G.T. Oh, W.F. Park, S.I. Park, S.K. Park, et al. **2006**. *Anti viral Res*, 72; 100-6.
- [18] S. Wong, M.M. Wong, O. Seligmann, H. Wagner, **1988**. *Tora. Phytochemistry* 28 (1), 211-214.
- [19] C.C. Lin, C.H. Chang, J.J. Yang, T. Namba, M. Hattori., **1996**. *J. Ethnopharmacol.*, 52, 107-111.
- [20] R. Anton, P. Duquenois, **1996**. *Ann. Pharm. Francaise*, 26 (11), 673-680.
- [21] J. Lal, P.C. Gupta., **1973 b**. *Experientia*, 29 (2), 141-142.

- [22] R.D. Tiwari and J. Singh ., **1977** b. *Phytochemistry.*, 16 (7), 1107-1108.  
[23] M. Singh, J. Singh., **1985**. *Planta Med.*, 51(6): 525-526.