



Arsenic induced oxidative stress, hemato-biochemical and histological changes in liver and protective effect of moringa leaf powder and ascorbic acid in broiler chicken

Sagi Tanju¹ and D. Madhuri²

¹Veterinary Assistant Surgeon, Hyderabad, India

²Department of Pathology, C. V. Sc., Rajendranagar, Hyderabad (Andhra Pradesh) India

ABSTRACT

The toxic effects of sodium arsenite, As (III) and its amelioration with Moringa leaf powder @ 0.1% and ascorbic acid @ 200 ppm in broiler chicken was investigated. In the present study, chicks of day-old age belonging to Vencobb strain were assigned to six groups (I,II,III,IV,V,VI) consisting of eighteen chicks in each group. Group I served as control (basal diet) and birds in group II were given sodium arsenite @ 200 ppm in basal diet for 42 days. Group III and IV were given Moringaoleifera leaf powder and ascorbic acid @ 0.1% and 200 ppm in basal diet respectively. Group V was fed, diet containing sodium arsenite @ 200 ppm and Moringa leaf powder @ 0.1% for 42 days. Birds in group VI were given with sodium arsenite @ 200 ppm and ascorbic acid @ 200 ppm in basal diet for 6 weeks. Six birds from each group were sacrificed at fortnightly intervals. Blood, serum and tissue samples were collected. Over all mean values of Hb, PCV and TEC levels in control groups were in normal range whereas levels were significantly ($P < 0.05$) decreased in toxin group. The serum biochemical assays showed significant ($P < 0.05$) reduction in total protein, albumin, globulin, while significant ($P < 0.05$) increase in AST, GGT was observed in group II birds. Oxidative stress parameters revealed significant ($P < 0.05$) decrease of liver GSH in group II. The ameliorative groups V and VI showed marked improvement in all the above parameters as compared to toxic group. Grossly group II birds revealed enlarged liver with hyperemia and extensive haemorrhages and histopathological lesions in group II comprised of severe sinusoidal and venous congestion with mononuclear cell infiltration. In conclusion, sodium arsenite caused a significant toxicity in broiler chicken and its amelioration with Moringa oleifera leaf powder and ascorbic acid was effective in combating the arsenic induced toxicity.

Key words: sodium arsenite, moringa leaf, ascorbic acid and chicken.

INTRODUCTION

Arsenic (As) toxicity is a global health problem affecting millions of people and animals. It is a naturally occurring metalloid, ubiquitously present in the soil and vegetation. Arsenic is second only to lead as a cause of heavy metal intoxication in domestic animals and is an environmental toxicant and carcinogen [1,2]. Liver is an important target organ of arsenic toxicity. Arsenic is methylated by alternating reduction of pentavalent arsenic to trivalent and addition of methyl group from S-adenosylmethionine [3]. Dimethylarsinic acid (DMA) and Monomethylarsinic acid are the predominant metabolites of inorganic arsenic are more toxic than the parent compound. It induces lipid peroxidation and Fe-dependent formation of reactive oxygen species (ROS) that leads to cellular damage and carcinogenesis [4] of various organs and tissues including skin, liver, lung and bladder.

Moringa oleifera belongs to Moringaceae family and is a multipurpose tree widely used in Indian traditional medicine. Moringa plant extracts were reported to be antioxidant [5], fungicidal, hypocholesterolemic, antidiabetic and antitumor activity [6].

L. ascorbic acid is a primary defensive nutrient as it reduces damage by scavenging free radicals generated by their metabolism. Keeping the above facts in view, an experiment was planned to study the effect of arsenic induced oxidative damage and protective effect of *Moringa oleifera* leaf powder and ascorbic acid @ in broiler chicken.

EXPERIMENTAL SECTION

One hundred and eight sexed male broiler chicks of day-old age belonging to Vencobb strain were brought for the experiment. They were divided into 6 groups of 18 birds each selected at random. Chicks were weighed and tagged with wing bands for identification. The chicks were reared in cage system and given feed and water ad libitum, from day one to 42 day's period. Experiment was carried out in Poultry experimental station, C.V.Sc. Rajendranagar, according to the guidelines and prior approval of institutional animal ethics committee.

Experimental design

Groups	No. of birds	Treatment
I	18	Basal Diet
II	18	Sodium arsenite (200 ppm) in basal diet for 6 weeks
III	18	Moringa leaf powder (0.1 %) in basal diet for 6 weeks
IV	18	Ascorbic acid (200 ppm) in basal diet for 6 weeks
V	18	Sodium arsenite (200 ppm) and Moringa leaf powder in basal diet for 6 weeks
VI	18	Sodium arsenite (200 ppm) and Ascorbic acid in basal diet for 6 weeks

Hematology-

Six birds from each group were randomly sacrificed at fortnightly intervals from second week onwards. Blood and serum samples were collected from each bird separately for haematological and biochemical estimations. Following blood parameters Hb, PCV and TEC were estimated by Whole blood analyzer (Huma Count, Medsource Ozone Biomedicals Pvt. Ltd.).

Biochemical assay

Biochemical assays like Aspartate amino transferase, Gamma-glutamyltransferase, total protein and albumin were analysed using various kits

Antioxidant defence profile

Liver samples of all the groups were collected at the time of slaughter and tissue homogenate was prepared and in that homogenate tissue protein, reduced glutathione (GSH) was estimated as described by Moron *et al.*, 1979[7].

Gross and Histopathological study

To study the gross and microscopic changes, six birds from each group were sacrificed at 2, 4 and 6 weeks of age. Detailed necropsy was conducted on all, the birds and gross changes in all vital organs if any were recorded. Pieces of liver tissue were collected in 10% neutral formal saline for histopathological examination. The fixed tissues were processed and stained with hematoxyline and eosin (H & E) stain as described by Culling, 1957 [8]. The sections were examined under light microscope.

Statistical analysis

The recorded data on haematological, biochemical and oxidative stress parameters were analysed statistically by two ways ANOVA [9].

RESULTS AND DISCUSSION

The haematological profile (Table 1) of the present study revealed that over all mean values of Hb, PCV and TEC were significantly ($P < 0.05$) decreased in Group II in comparison to other groups. The reduction might be due to its effect on haem and porphyrin synthesis. Arsenic causes inhibition of blood aminolevulinic acid dehydratase (ALAD) activity resulting in disturbed haem synthesis pathway [10]. Binding ability of arsenic to Hb led to inhibition of haem synthesis and other parameters were also disturbed because these are dependent on each other.

The ameliorative groups V and VI showed significant improvement when compared to the group II but lower values than Groups I, III, IV. Similarly, improvement in blood aminolevulinic acid dehydratase activity was noticed by Gupta *et al.*, (2005) in rats on oral administration of Moringa seed powder.

The mean total protein, albumin and globulin concentration (g %) of Group II (1.84, 0.36 and 1.47) was significantly ($P < 0.05$) reduced when compared to all other groups (Table 1). The values however were comparable among the

ameliorative groups V and VI. Decreased protein levels could be attributed to their damage by singlet oxygen, often due to oxidation of essential amino acids [12] and also due to increased catabolism.

Normal Protein profile was found in control groups I, III and IV while ameliorative groups V and VI showed increased levels of total serum protein as compared to group II. Ascorbic acid and Moringa leaf powder supplementation was found to be effective in increasing the level of serum protein and albumin indicating these might have aided in the adaptation to stressful condition.

Arsenic is known to produce disturbances in liver function [13].

The mean AST Values in group II (126.39) was significantly ($P < 0.05$) higher than all other groups (Table 2). The results correlated with the findings of several workers [14,15,16,17].

The mean AST activity in groups I, III and IV (83.05, 90.61 and 85.27) respectively were comparable with each other. The mean values of groups V and VI (107.39 and 100.05) were comparable each other and showed significantly ($P < 0.05$) lower value than group II.

Umar *et al.*, (2000) concluded that ascorbic acid supplementation ameliorated oxidative stress there by sparing endogenous antioxidant reserve and protecting tissues and organs against damage.

The mean GGT activity of group II (17.11) recorded significantly ($P < 0.05$) higher value than group I (2.39) while the mean values of group V and group VI (16.50 and 16.71) were comparable with each other (Table 2). The mean values of groups III and IV (5.36 and 4.59) were comparable with each other and showed significantly ($P < 0.05$) higher values than group I (2.39).

Decreased activity of GGT in treatment groups V and VI is indicative of protective action of Moringa leaf powder and ascorbic acid against liver damage caused by arsenic. GSH is a critical component of antioxidant defense system. In the present study, reduced GSH concentration was observed in group II as compared to other groups (Table 2). Similar observations in other species were noticed by [19,20,21] in rats. Trivalent arsenicals react *in vitro* with thiol containing molecules such as glutathione, cysteine or haemoglobin forming AS-SH complex or $(GS)_3AS(III)$ with GSH [22] and this property is considered to be the mechanism of action by which arsenic exerts its toxic effect. Arsenic generated ROS also attack SH groups thus leading to their oxidation, thus damaging proteins and enzymes requiring SH groups.

The groups V and VI showed a significant ($P < 0.05$) increase in GSH as compared to group II showing the ameliorating effect. These findings were in agreement with Gupta *et al.*, (2007) who reported *Moringa oleifera* seed powder protects tissues from oxidative stress. Similar antioxidant effects in liver and kidney were observed in ascorbic acid treated rats by Sohini Singh and Rana (2007) and Banerjee *et al.*, (2009).

Liver of arsenic treated group revealed moderate enlargement and hyperaemia whereas mild to no gross changes were noticed in ameliorative groups

Histologically mild to marked venous congestion (fig1), sinusoidal dilatation, multiple foci of mononuclear cell infiltration, parenchyma disorganization were observed. Similar lesions of parenchyma disorganization (Pires Das Naves *et al.*, 2004), necrosis and fibrosis in periportal region (Mandal *et al.*, 2006) were observed in arsenic induced toxicity in rats.

Hepatic necrosis might be due to oxidative stress induced by arsenic that further involved in cellular protein degradation. The sinusoidal spaces were expanded due to shrinkage and necrosis of hepatic cells. Sections of liver of group VI revealed mild sinusoidal congestion and dilation (fig 2). Similar findings were observed in liver treated with arsenic and ascorbic acid in rats by Sohini Singh and Rana (2007).

In conclusion, the results of the present study revealed that feeding of arsenic @ 200 ppm for a period of 42 days caused significant ($P < 0.05$) changes in growth, haematobiochemical and pathological changes. This might be due to the toxic metabolites and formation of toxic free radicals. Supplementation of Moringa leaf powder and ascorbic acid resulted in significant ($P < 0.05$) improvement in the above parameters.

Ascorbic acid is the strongest reductant and radical scavengers and reduces stable oxygen produced in arsenic toxicity and acts as a primary defense against ROS.

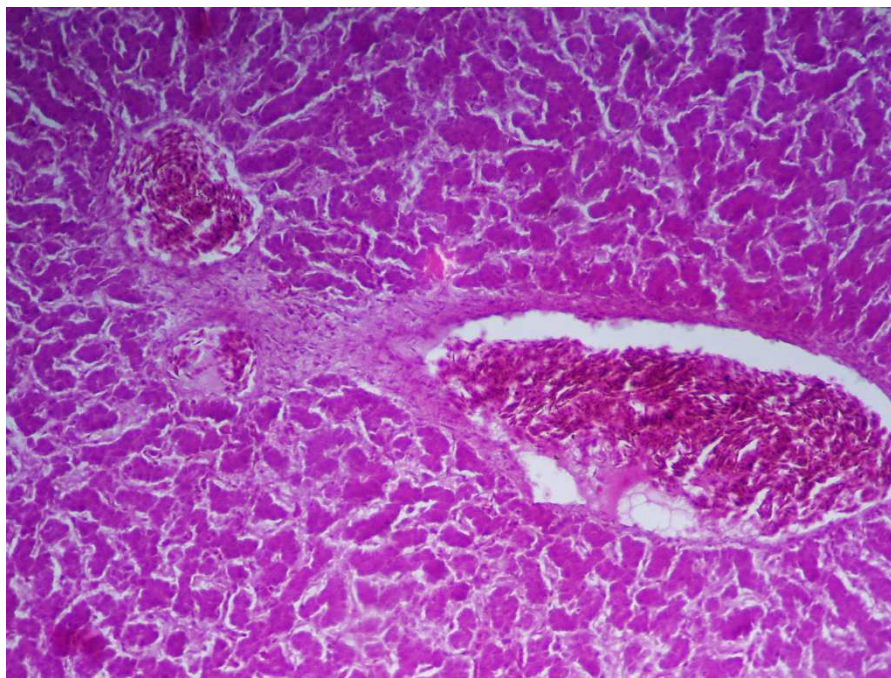


Fig 1- Microphotograph of liver from group II birds showing severe venous congestion and marked sinusoidal dilatation at sixth week H & E X400

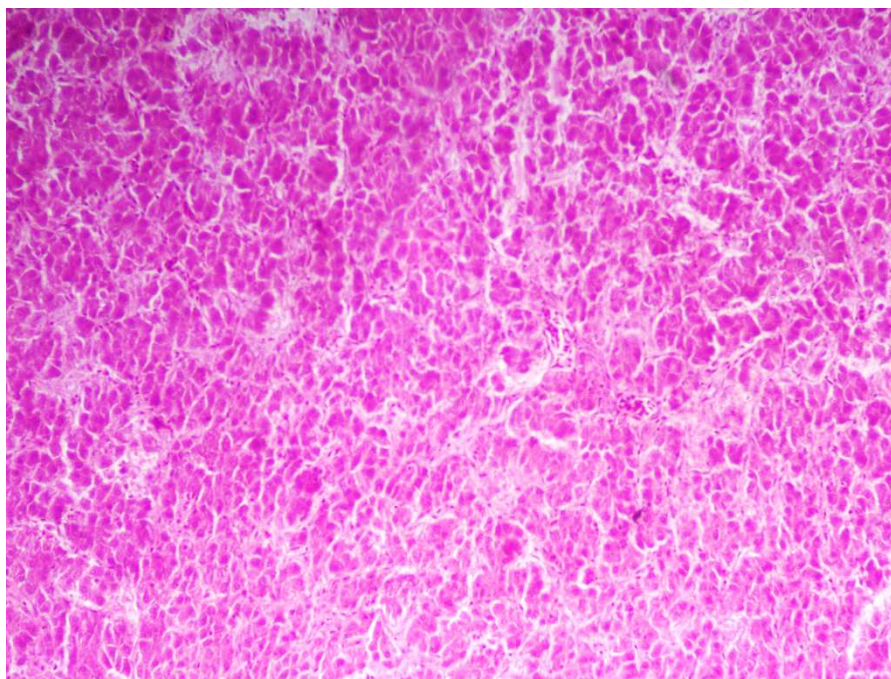


Fig 2- Microphotograph of liver from group VI birds showing mild sinusoidal congestion and dilation at sixth week H & E X200

TABLE1. Mean hemoglobin (g/dl), PCV (%),TEC (millions/cmm), total protein,albumin and globulin (g %) in different groups of birds.

GROUPS	HB	PCV	TEC	TOTAL PROTEIN	ALBUMIN	GLOBULIN
GI	12.42±0.06 ^c	24.88±0.42 ^d	2.02±0.04 ^d	5.05±0.17 ^d	1.86±0.25 ^d	3.19±0.18 ^a
GII	8.83±0.24 ^a	21.50±0.43 ^a	1.23±0.04 ^a	1.84±0.09 ^a	0.36±0.04 ^a	1.47±0.15 ^c
GIII	12.34±0.09 ^c	24.38±0.72 ^d	1.84±0.06 ^c	4.25±0.21 ^c	0.98±0.11 ^c	3.25±0.13 ^a
GIV	12.28±0.29 ^c	24.16±0.38 ^d	1.72±0.02 ^c	4.05±0.21 ^c	1.13±0.08 ^c	2.91±0.15 ^b
GV	10.03±0.20 ^b	22.60±0.56 ^b	1.43±0.04 ^a	2.53±0.15 ^b	0.59±0.09 ^b	1.90±0.17 ^c
GVI	10.51±0.44 ^b	23.52±0.49 ^c	1.35±0.07 ^a	2.42±0.14 ^b	0.72±0.13 ^b	1.69±0.18 ^c

TABLE2. Mean AST(IU/L), GSH (mg/g) and GGT(IU/L) in different groups of birds.

GROUPS	AST	GSH	GGT
GI	83.05±6.52 ^a	12.17±0.25 ^c	2.39±0.30 ^d
GII	126.39±10.71 ^c	8.55±0.18 ^a	17.11±2.23 ^b
GIII	90.61±6.70 ^b	12.03±0.27 ^c	5.36±1.42 ^c
GIV	85.27±6.68 ^b	12.12±0.25 ^c	4.59±0.95 ^c
GV	107.39±7.48 ^b	9.04±0.28 ^b	16.50±3.04 ^b
GVI	100.05±6.09 ^b	9.10±0.43 ^b	16.71±3.46 ^b

REFERENCES

- [1] IARC ,Hum.Suppl. **1987** , 7: 100-103.
- [2] NRC .**1999** .,In NRCR Washington D.C. , National academy press , 1-310.
- [3] E.Marafante ;M.Vahter; J. Envall. *Chem . Biol.Interact.*,**1985** , 56 : 225-238.
- [4] S. Ahmad; KT.Kitchin; WR. Cullen.*Arch. Biochem. Biophys.*,**2000**, 382 , 195-202.
- [5] P.Siddhuraju ; K. Becker . *J. Aric. Food chem.*,**2003** , 51 : 2144-2155 .
- [6] R.Gupta ; G.M.Kannan ; M.Sharma ; SJS.Flora.*Environ Toxicol and Pharmacol***2005** , 20 , 456-464.
- [7] MS.Moron; JW.Depierre; B.Mannervik. *Biochem and Biophys.Acta.*1979,582,67-68.
- [8] CFA. Culling. Handbook of histopathological technique. **1957**, London butterworth and Co (publisher) Ltd.
- [9] WG.Snedecor; GW. Cochran. Stastistical Methods. **1994**, 8th edition, Iowa State University Press, Ames, USA.
- [10]R.Gupta ;SJS.Flora.*Hum.Exp. Toxicol.* , **2006** ,26(6) , 285-295.
- [11]B.Halliwell ; JMC.Gutteridge .Free radicals in biology and medicine. Clarendon press Oxford. , **1985** .
- [12]BA.Flower.;JS.Woods.; CM.Schiller. *Environ. Hlth.Perspect.***1977** , 19 , 197-204.
- [13]SJ. Flora.;SC.Pant.; PR.Malhotra;GM. Kannan .*Alcohol*,**1997** ,14(6) , 563-568
- [14]Santra. ; A.Maiti; S. Das.; S. Lahiri .;SK.Charkaborty ;N. Debendra ; G.Mazumdar . *Clin.toxicol.* ,**2000**, 38(4) ,395-405.
- [15]Jun wu ; Jie Liu ; M.P. Waalkes ; M.L. Cheng ; Ling Li ; Cheng-Xiu Li ; Quing Yang , *Exp.Biol. Med.* **2008** , 233, 377-384.
- [16]M.Roy ;PK. Pandey ;S.Roy.*Ind. Vet. J.*,**2009** , 86: 570 -572 .
- [17]IA.Umar ;ZA. Toh.; FI. Igbalajobi. ; Abubarkar-Gidado ; LB.Burtai .*J. Clin. Boichem .Nut.* , **2000** , 28 ,1-7 .
- [18]R.Gupta ;SJS.Flora.*Phytother. Res.* , **2005**, 9(1) , 23-28.
- [19]S. Singh ;SVS. Rana.*J. Environ.Biol.*, **2007** , 28 (2) : 377-384 .
- [20]NJ.Chinoy .; SD.Shah.*Fluoride* ,**2004**, 37, 80-87.
- [21]P.Hemalatha;A.GopalaReddy;Y.Ramana;P.ShivaKumar.*J.of Chemical and Pharmaceutical Res.*,**2012**,4 (10): 4459-4461.
- [22]R.Gupta.;DK.Dubey; GM.Kannan G.M. ;SJS. Flora.*Cell. Biol. Intl.*, **2007** , 31(1) , 44-56.
- [23]P.Banerjee ;SS.Bhattacharya; N. Bhattacharjee.; S.Pathak ; N.Boujedaini ; P.Belon ; AR.Khuda-bukhsh . *Ecotoxicol Environ Saf.* ,**2009** ,72(2) ,639-649.
- [24]RN.Pires Das Neves. ; F. Carvalho ;M. Carvalho; E. Fernandes , E.Saores, M. De L. Bastos ; M. De L. Pereira .*Toxicol.Path.* , **2004** , 32 : 527-535 .
- [25]AK.Mandal ; Sudhakar Das ; M.K.Basu; R.N. Chakrabarti ; N. Das .*J. Pharmacol. Exper. Therap .* ,**2006** , 320 : 994-1001.