



## An anatomical study of formation of the median nerve

Humberto Ferreira Arquez<sup>1\*</sup> and Diana Katherine Arias Hurtado<sup>2</sup>

<sup>1</sup>Professor of Human Morphology, Medicine Program, Morphology Laboratory Coordinator, University of Pamplona Pamplona, Norte de Santander, Colombia, South America

<sup>2</sup>Medicine Student Twelfth Semester - University of Pamplona

---

### ABSTRACT

Anatomical variations in the formation of the median nerve are common. The third root of median nerve is of great academic and clinical significance in orthopedics, surgery, anaesthesiology, Neurophysiology, Physiatrists, Sports medicine and Physiotherapy. The aim of this study was to analyze the anatomical variations in the number of root of median nerve. A total of 14 cadavers were used for the study in the laboratory of Morphology of the University of Pamplona. It was observed that the left median nerve had three roots (one medial and two laterals). The third root originated between the origins of the lateral root and the musculocutaneous nerve from lateral cord of brachial plexus. The significance of the variations of the brachial plexus is relevant in the management of surgical exploration of the axilla and in the nerve blocks procedures of the brachial plexus.

**Keywords:** Anatomical variations, median nerve, additional lateral root, brachial plexus, axillary artery, musculocutaneous nerve.

---

### INTRODUCTION

The brachial plexus is a complex structure which is divided into roots, trunks, divisions, cords and branches, has supraclavicular and infraclavicular part. The supraclavicular part includes roots, trunks and divisions. The infraclavicular part includes cords and their branches. The brachial plexus is formed by the union of ventral rami of C5, C6, C7, C8 and greater part of T1. These ventral rami are the roots of brachial plexus, almost equal in size but variable in their mode of junction. Ventral rami of C5 and C6 unite at the lateral border of the scalenus medius to form upper trunk and C7 continues as middle trunk while C8 and T1 unite behind scalenus anterior to form lower trunk. All these trunks incline laterally, just above or behind the clavicle where each one bifurcates into anterior and posterior divisions. The anterior divisions of upper and middle trunks unite to form a lateral cord, lateral to the axillary artery and the anterior division of the lower trunk descends at first behind, then medial to the axillary artery, forming medial cord. Posterior divisions of all the three form the posterior cord, at first above and then behind the axillary artery [1-3]. The brachial plexus supplies cutaneous and muscular innervation to the upper limb and any injury at this level can lead to significant disability. From the cords arise the terminal branches of the brachial plexus including the musculocutaneous (MCN), median (MN), ulnar, axillary, and radial nerves. Variations of the cords and their terminal branches of the brachial plexus are relatively common and have been well documented. It is important for the anatomist, surgeon, anesthesiologist, and radiologist to be aware of anatomical variations that deviate from the classic anatomy. Variations of the brachial plexus regarding its origin, level of junction or separation of cords, composition of fiber bundle, pre-fixation, post-fixation, relations with subclavian and axillary artery and absence or communication between its branches are common and are being reported by several authors.

Amongst the several variations noted, the communication of the MN with the MCN has been noted to be the commonest. In classical description the median nerve originates by two roots from the lateral (C5, 6, 7) and medial cords (C8, T1) of brachial plexus. These roots join in the form of letter 'Y' and embrace the third part of axillary artery. The nerve enters the arm first lateral to the brachial artery and then crosses from lateral to medial side of this vessel by passing anterior to it near the insertion of coracobrachialis, further it descends medial to it and proceeds towards the cubital fossa where it lies posterior to the bicipital aponeurosis and anterior to the brachialis. It usually enters the forearm between the humeral and ulnar heads of Pronator teres muscle. The entrapment of median nerve at this level presents with features like that of carpal tunnel syndrome plus involvement of palmer cutaneous nerve. In the forearm it descends posterior and adherent to the flexor digitorum superficialis and anterior to the flexor digitorum profundus. About 5 cm proximal to the flexor retinaculum, it emerges behind the lateral margin of the flexor digitorum superficialis and becomes superficial just proximal to the wrist between the tendons of flexor digitorum superficialis and flexor carpi radialis. The median nerve is the only branch of brachial plexus which passes deep to the flexor retinaculum into the palm where its compression leads to carpal tunnel syndrome. In the arm, median nerve gives vascular branches to brachial artery which carry sympathetic fibers and muscular branches to the pronator teres at a variable distance from elbow joint. It innervates all flexors in the forearm except Flexor Carpi ulnaris and the medial two digitations of flexor digitorum profundus which are supplied by the ulnar nerve. The median nerve then enters hand deep to the flexor retinaculum along with the tendons of flexor digitorum superficialis, flexor digitorum profundus and flexor pollicis longus. From here it gives a recurrent branch which innervates the lateral two lumbricals and muscles of the thenar eminence namely opponens pollicis, abductor pollicis brevis, and flexor pollicis brevis. It also gives digital cutaneous branches which supply the lateral three and a half digits on the palmer side, index, middle and ring finger on the dorsal side of the hand. The palmer cutaneous branch passes over flexor retinaculum and is therefore spared in carpal tunnel syndrome [4,5]. The aim of this study was to analyze the anatomical variations in the number of root of median nerve from its origin to the formation.

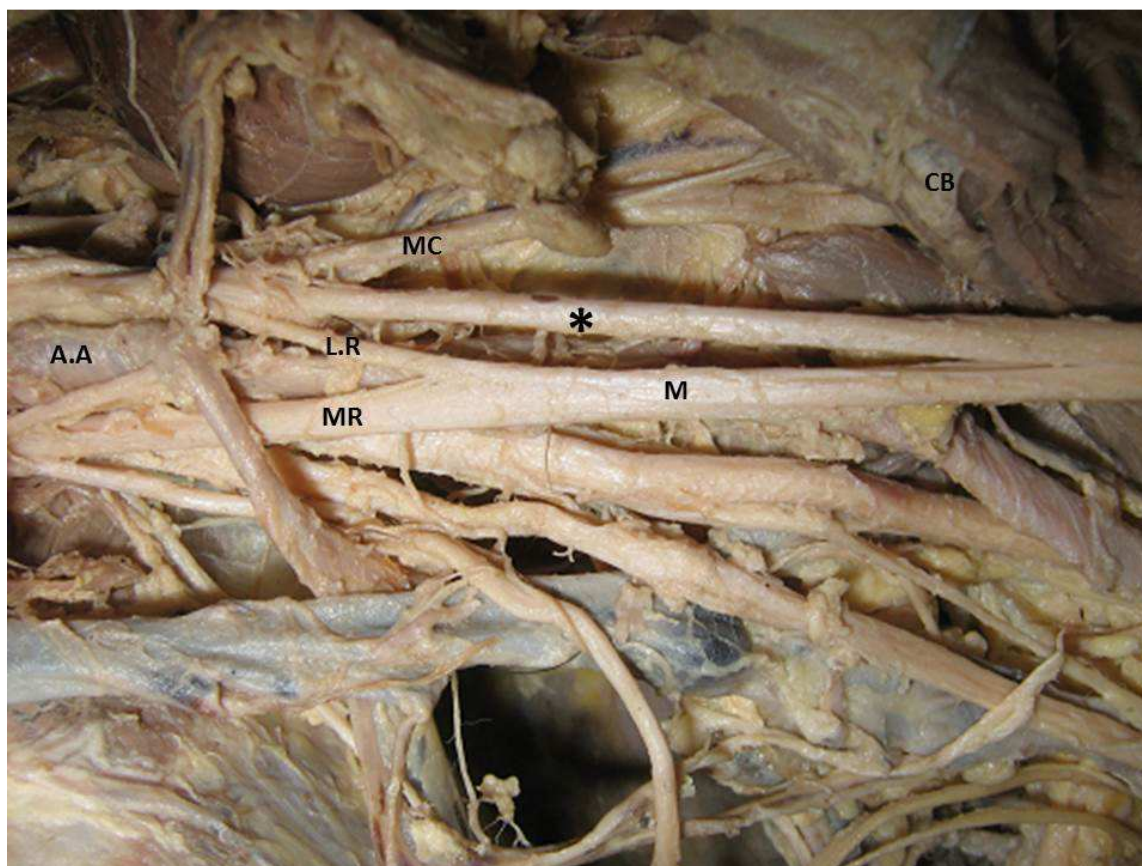
### EXPERIMENTAL SECTION

A total of 14 cadavers of both sexes (13 men and 1 women) with different age group were used for the study. Upper limb regions(28 sides) of the cadavers were carefully dissected as per the standard dissection procedure in the Morphology Laboratory at the University of Pamplona. The dissection was performed followed the anatomical plans. The dissection was initiated by the anterior surface of the elbow joint, followed medially through the arm and shoulder area, to the origin of the brachial plexus in the cervical region. The median nerve was identified and a detailed observation of the fascicles of the brachial plexus as well as of the roots that formed the median nerve and the terminal branches of the brachial plexus was made. Each observed variation of the median nerve was identified, photographed and recorded, taking into account gender, level and side of the upper limb.

### RESULTS AND DISCUSSION

The pectoral region, axilla and arm were dissected. The axillary artery and the cords of the brachial plexus and the branches of the cords were identified. We studied the origin and course of the musculocutaneous nerve and median nerve and their relationship with the surrounding structures. We found anatomical variations in the formation of the median nerve in 1 (3,57%) in the left side limb of the 28 dissected brachial plexus. In the left upper limb of male cadaver of 65 years old. It was observed that the median nerve had three roots; one each coming from the lateral cord, medial cord and the musculocutaneous nerve. A lateral root originated from the lateral cord and joined the medial root to form the main trunk of the median nerve on the medial side of the axillary artery, 3.0 cm distal to the tip of the coracoids process. A third root of the median nerve emerged from the musculocutaneous nerve before the latter pierced the coracobrachialis muscle. The third root run downward along the lateral side of third part of axillary artery and brachial artery and joined the main trunk of median nerve about 14.5 cm distal to the tip of the coracoid process (Figure 1). Total length of third root was 11.6 cm and the thickness was about 3,1 mm. It was larger than the lateral root. The remaining anatomical course and branching pattern of median nerve in this limb was normal. The origin, course and branching pattern of median nerve on the right side of this cadaver was normal.

The distribution of musculocutaneous nerve was normal. It supplied the coracobrachialis, biceps brachii and brachialis muscles and just below the elbow it continued as cutaneous nerve supplying the lateral aspect of forearm.



**Figure 1. Photograph of the dissected left arm**

*A.A: Axillary Artery; M.C: Musculocutaneous nerve; M.R: Medial root of median nerve; L.R: Lateral root of median nerve; M: median nerve; Asterisk: third root of median nerve; C.B: Coracobrachialis muscle.*

Understanding the embryological stages in development of brachial plexus is important for explaining possible anatomical variants. The upper limb bud appears at 26–27 days in the developing embryo and motor axons from the spinal cord enter the limb bud during the fifth week [6]. During histogenesis of peripheral nerves, the normal development of peripheral nerve network depends upon ability of axons to locate and recognize their appropriate target. Developing axons choose specific routes in the embryos during path finding stage followed by growth cones navigating towards their targets. Axons' targets may be far away from their soma and they generally pass through intermediate targets to form axon networks. The terminal enlargement of a growing axon – 'the growth cone', arises from filopodia and leads the growth of an axon along its route. The growth cone is a sensory-motor organ that recognizes and responds to guidance cues that are present along the path in the surrounding environment. The cues are generally molecules, which act as chemoattractants or chemorepellents. Reacting to these cues the axon navigates over long distances to find the correct target [7]. Axons reach distant targets in a series of discrete steps, making decisions at relatively frequent intervals along the way. The axons take variety of paths to reach their destination. Some grow directly to their termination site; but others make a variety of apparent 'decision mistakes' and then change course or extend new branches. This is because different axons respond differently to a particular chemical molecule. Such corrections imply the existence of positional cues [8]. This probably explains why variations do occur in the course of a nerve and also that the nerve fibers ultimately reach their destination. In doing so, they give rise to many such branches which are not seen usually and are regarded as variations [9].

There are various reports in the literature about the variations in the origin, course, branching pattern and modes of termination of the median nerve. These variations are commonly encountered during surgical procedures, dissection and autopsy. A thorough anatomical knowledge of these variations is very useful for Surgeons, Orthopaedicians, Interventional Cardiologists, Radiologists, Neurophysiologists and Anaesthetists. Variations about the number the roots of median nerve have been reported by many workers. Median nerve as reported in literature, is associated

with several variations which include abnormal communications with other nerves such as musculocutaneous and ulnar nerves [2,3,10], splitting of the median nerve [11] and unusual innervations of flexor muscles of arm by the median nerve [12,13]. Variations in the formation of median nerve (MN) were reported by some earlier workers and were related to variant relationship between MN and musculocutaneous nerve (MCN). Study done by Satyanarayana and Guha found a four rooted MN with three lateral and one medial root [14]. Pandey and Shukla have found in 4.7% cases that the roots of MN joined on medial side of axillary artery, and in 2.3% cases the roots did not join but continued separately [15]. Budhiraja V, et al. reported that anterior division of upper trunk continues as lateral cord along with variant formation of median nerve [16]. Study done by Eglseider and Goldman investigated that the MN nerve was formed of two lateral roots in 14% of their specimens [17]. Chauhan and Roy reported formation of MN by two lateral and one medial roots [10]. Badawoud reported a communicating branch from upper part of a lateral root to lower part of the medial root of median nerve, in one out of four anomalies found in a series of 48 dissected limbs [18]. A study done by Nene, et al. reported a rare posterior union of the two roots, with the thus formed MN coursing behind the axillary and brachial arteries till the cubital fossa [9]. Itoo M S, et al. reported a rare anomaly of brachial plexus, on the right side of an Indian male cadaver, where medial and lateral cords of brachial plexus joined and formed a common anomalous nerve. This nerve then divided into medial and lateral components. The lateral division further gave origin to a smaller branch proximally which pierced coracobrachialis muscle and continued as a large branch which supplied other muscles of the Flexor compartment of arm. The larger medial branch continued as MN [4]. Studies on fetuses by Uysal, et al. reported the variations of the brachial plexus to be more common in females and on the right side [19]. Anomalies of nerves are accompanied by abnormalities of vessels. The variations of brachial plexus were associated with those of subclavian, axillary and brachial arteries [20]. So many studies are done but in rare cases such type of variation of the formation of MN by two roots from lateral cord of brachial plexus which are surrounding the axillary artery are less found [21].

The anatomical variations of NM have been highlighted within the context of their clinical significance. In this sense we can emphasize its importance in preventing undesirable surgical outcomes [22]; clinical diagnosis [23]; orthopedic surgeries in the neck of the humerus and the MN lesions in the axilla or arm [24]; surgical exploration of the axilla and brachial plexus block [25]; traumatic shoulder injuries and especially in the dissection of axillary lymph nodes in cases of breast cancer [2,3,26-29].

## CONCLUSION

The anomalies of median nerve have definite embryological basis and diverse clinical presentations. Knowledge of such anatomical variations is of interest to the anatomist and clinicians. Variations assume significance during surgical exploration of the axilla and can even fail nerve block of infraclavicular part of brachial plexus. Surgeons who perform procedures involving neoplasm or repairing trauma needs to be aware of these variations. The median nerve with extra roots is more likely to be involved in entrapment syndromes and while performing orthopaedic and other surgical interventions and may lead sensory, motor, vasomotor and trophic change.

## Acknowledgements

The author thanked to the University of Pamplona for research support and/or financial support and Erasmo Meoz University Hospital for the donation of cadavers identified, unclaimed by any family, or persons responsible for their care, process subject to compliance with the legal regulations in force in the Republic of Colombia.

## REFERENCES

- [1] DH Gopalan, *IJAV*, 2014, 7, 103-105.
- [2] AH Ferreira, *IJGMP*, 2014, 3(2), 71-78.
- [3] AH Ferreira, *Int J Pharm Bio Sci*, 2015, 6(2), (B), 951 –957.
- [4] M Itoo et al, *International Journal Of Basic And Applied Scienc*, 2014, 3(3), 254-256.
- [5] RR Sakharam et al, *IJAV*, 2013, 6, 74-76.
- [6] KL Moore, TVN Persaud. The developing human: Clinically oriented embryology, 7th Ed, W.B. Saunders Company, Philadelphia, 2003; 410- 458.
- [7] S Kaplan; E Odaci; B Unal; B Sahin; M Fornaro, *Int Rev Neurobiol*, 2009, 87, 9–26.
- [8] TM Jassell, JR Sanes. The guidance of axons to their targets. In: Principles of neural sciences, 4th Ed, McGraw-Hill, Columbia, 2000; 1063–1084.
- [9] AR Nene; KS Gajendra; MVR Sarma, *IJAV*, 2010, 3, 138-140.

- 
- [10] R Chauhan;TS Roy,*Journal of anatomical society of India.*, **2002**, (51), 72-75.
- [11] SM Sundaram; MS Kumar; BB Sethupathi;S Nayak; AKrishnamurthy,*Neuroanatomy.*,**2008**,(7): 15-6.
- [12] S Nayak,*Neuroanatomy.*,**2007**, (6),49-50.
- [13] V Budhiraja;R Rastogi;AK Asthana,*J. Morphol. Sci.*,**2011**, 28 (4), 283-286.
- [14] N Satyanarayana;R Guha, *J Coll Med Sci.*, **2008**, 5, 105–107.
- [15] SK Pandey;VK Shukla, *Clin Anat.*,**2007**,(20), 150–156.
- [16] V Budhiraja;R Rastogi;S Khare;S Jain,*People's journal of scientificresearch.*,**2009**, 2(1), 17-18.
- [17] WA Eglseeder Jr;M Goldman,*Am J Orthop* (Belle Mead NJ),**1997**,(26), 777–780.
- [18] MHM Badawoud,*Bahrain Medical Bulletin.*,**2003**, 25(4), 1-5.
- [19] II Uysal;M Seker;AK Karabulut;T Ziylan,*Neurosurgery.*, **2003**, 53(3), 676-684.
- [20] MF Sargon;SS Uslu;HH Celik;D Aksit,*Bull Assoc Anat.*,**1995**,(79), 25–26.
- [21] BB Prakash;JY Singh,*IAIM.*, **2015**, 2(1), 112-115.
- [22] RD Leffert,*Instr Course Lect.*,**1989**,(38),245-253.
- [23] D Choi;M Rodríguez-Niedenführ;T Vázquez;I Parkin;JR Sañudo,*Clin Anat.*,**2002**,15(1),11-17.
- [24] SP Sawant;ST Shaikh;RM More,*IJMPS.*, **2012**,3(3),35-43.
- [25] V Budhiraja;R Rastogi;AK Asthana;P Sinha;A Krishna;V Trivedi, *Ital J Anat Embryol.*,**2011**,116(2),67-72.
- [26] M Radunovic; A Vukasanovic-Bozagic; N Radojevic; T Vukadinovic,*Folia Morphol (Warsz.)*, **2013**,72(2),176-179.
- [27] F Prado et al,*Annual Research & Review in Biology.*,**2014**, 4(14), 2347-2356.
- [28] J Butz et al,*Australasian Medical Journal.*,**2014**, 7 (5), 227-231.
- [29] R Seifali et al, *Anatomical Sciences.*,**2014**, 11(3), 155-57.