



An anomalous accessory muscle belly of the second lumbrical with bifurcated insertion of third lumbrical, and their relevance with carpal tunnel syndrome

Ishwar B. Bagoji^{1*}, M. A. Doshi², Gavishiddappa A. Hadimani¹, Balappa M. Bannur¹,
Shardha Bai Rathod³ and B. G. Patil¹

¹Dept. of Anatomy, BLDE University's Shri B M Patil Medical College, Bijapur, Karnataka, India

²Dept. of Anatomy, Krishna Institute of Medical Sciences University, KIMS Karad

³Dept of Oral Medicine & Radiology, Pandit Deen Dayal Dental College, Solapur, Maharashtra

ABSTRACT

There are many anatomical variations in muscle belly, tendons, nerves, and arteries in hand. Awareness of these variations is very important during diagnosis and treatment of carpal tunnel syndrome during hand surgery and plastic surgery. We report here the presence of an anomalous muscle in the hand between the first and second lumbricals. The muscle was taking origin from the ulnar side of the flexor digitorum profundus and inserted in to radial side of the dorsal digital expansion of the middle finger. The third lumbrical distally bifurcated and inserted in to dorsal digital expansion of the middle and ring finger. The abnormal muscle can produce a bulge in the palm and it might compress the median nerve in the carpal tunnel, resulting in carpal tunnel syndrome. A thorough knowledge of the anatomy of the carpal tunnel is essential in order to avoid complications and to ensure optimal patient outcome.

Keywords: Lumbricals, carpal tunnel syndrome, dorsal digital expansion, flexor digitorum profundus

INTRODUCTION

There are four lumbricals (resembling the shape of earthworm) in each hand. Compared to their small size, they play a very significant role in the dynamics of the intricate movements of the fingers required for the precision work. Lumbricals are described as work horse of the extensor apparatus, the only muscle in the body that is able to relax the tendon of its own antagonists. The muscles arise from the bare areas of tendons of flexor digitorum profundus (FDP) about the middle of palm pass distally along the radial side of metacarpophalangeal joints anterior to deep transverse metacarpal ligament. The narrow tendon of insertion joins the radial margins of extensor expansion as distal wing tendon¹. Normally the first and the second lumbricals are unipennate and third and fourth are bipennate. The lumbrical muscles are the link of the proximal system and provide dynamic controlled extension of the interphalangeal joints. Lumbricals produce flexion at metacarpophalangeal joint and extension at interphalangeal joints. These muscles also play a significant role in proprioception. Few of the variations have been described in the literature, ranging from complete absence to reduction in their numbers or presence of accessory slips². Variation similar to the present case has not been reported in earlier studies. Variations of lumbrical muscles in attachment and innervation are common. The study of innervation of lumbrical helps to know the aetiology in the paralysis of the muscle and in electrical stimulation, physiotherapy and plastic reconstruction in leprosy. The proximal attachment of lumbricals especially first and second may predispose to the development of carpal tunnel syndrome, in those individuals whose occupation requires repetitive finger movement.

EXPERIMENTAL SECTION AND RESULTS

During routine dissection of the right upper limb of an approximately 69 year old male cadaver, we observed an accessory muscle belly took origin from the ulnar side of the 1st flexor digitorum profundus tendon at the level of the proximal border of the flexor retinaculum. The accessory muscle belly was placed lateral to the second lumbrical and inserted separately to the Dorsal Digital Expansion (DDE) of the middle finger. The first lumbrical muscle took origin from the radial side of the Flexor Digitorum Profundus (FDP) tendon for the index finger and second lumbrical muscle took origin from the radial side of the FDP tendon for the middle finger as expected. Both the second lumbrical muscle and the accessory muscle belly were innervated by a twig from the median nerve. The third lumbrical muscle belly bifurcated into 2 slips close to the insertion, both the divided slips attached to the ulnar and radial side of the Dorsal Digital Expansions for the middle and ring fingers. The third lumbrical was innervated by ulnar nerve (Figure-1).

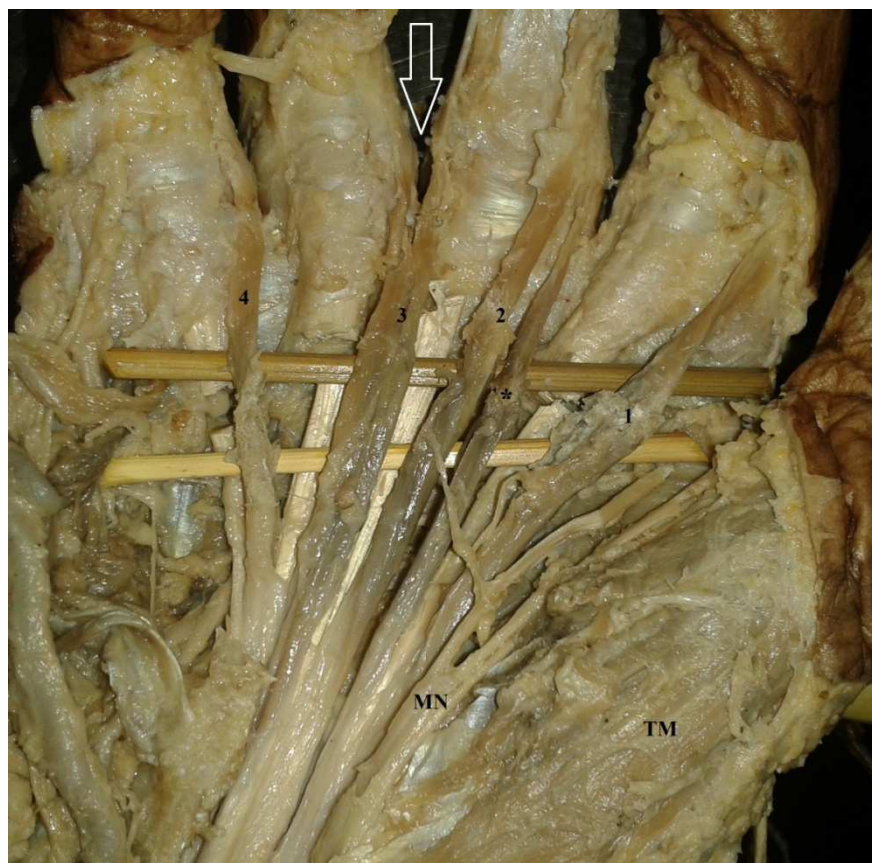


Figure 1: Dissected hand showing accessory lumbrical muscle, 1- 1st Lumbrical, 2- 2nd Lumbrical, 3-3rd Lumbrical, 4-4th Lumbrical, *Accessory muscle belly of second Lumbrical, ↑ Bifurcated insertion of third lumbrical muscle MN-Median Nerve, TM- Thenar Muscles

DISCUSSION

The articular system in the digits is connected by mechanical links and lumbrical muscle is one of the links of this system that produces dynamic controlled extension of interphalangeal joints³. It is very important for clinicians to be aware of the anomalous muscle may simulate a ganglion^{4, 5}. When they are closely related to the nerves they may result in carpal tunnel syndrome⁶. Many such anomalous symptomatic muscles have been reported; Ajmani⁷ clarified three new terminologies by comparing with the results of Mehta and Gardner⁸. These are additional forearm origin, double or supernumerary lumbricals and accessory belly. Additional forearm origins are those fibres originating from the forearm. These merge at the varying point with the belly coming from the palmar origin and in no case reach the extensor expansion independently for insertion. Accessory belly is an additional origin from the tendons of flexor pollicis longus, flexor digitorum superficialis, FDP and metacarpals in the palm and eventually attached to the main belly. Double or supernumerary lumbricals are those fibres originate from the forearm or in the palm and reach the insertion in extensor expansion independently. So anomalous belly observed in this case study will be known as accessory belly of second lumbricals.

Carpal tunnel syndrome is manifested by characteristic signs and symptoms resulting from compression of the median nerve at the wrist joint. The causes which produce this syndrome are e.g. i) trauma related like lunate dislocation, post traumatic arthritis etc. ii) in certain, systemic diseases e.g. Rheumatoid arthritis, hypothyroidism, amyloidosis etc. iii) hormonal e.g. pregnancy, menopause, iv) neoplasm's e.g. lipoma, ganglion, v) anomalous anatomical structures e.g. muscles like lumbricals extending into CT along with mechanical overuse e.g. highly repetitive wrist and finger movements⁹. The causes of this compression can be divided into the following groups: (1) diminution of the volume of the carpal tunnel, (2) increase in the volume of the structures which together with the median nerve pass through the carpal tunnel, (3) accompanying symptom in a systemic disease. Included in the abovementioned groups (1) and (2) are the rare cases of carpal tunnel syndrome caused by anatomical variants. It was observed that during finger flexion, lumbrical muscle incursion into the carpal tunnel takes place. They suggested that incursion is a normal occurrence and is a possible cause of work related CTS. To find out the CTS due to lumbricals muscle incursion in Carpal tunnel¹⁰. T K Cobb described 'fist test' In this test, person is asked to keep the hand in sustained fist position for 45 seconds it would result in numbness in the area of distribution of median nerv¹¹. Our finding in the present case was that the site of origin of second lumbrical and accessory belly was more proximal and extended into the carpal tunnel, and took origin from the first flexor digitorum profundus and inserted into the dorsal digital expansion of the middle finger. They will increase the volume of carpal tunnel contents and may lead to the CTS. So, from this discussion we can conclude that occurrences of such anomalous muscle belly may compress the median nerve and may leads to the CTS.

CONCLUSION

A thorough knowledge of the anatomy of the carpal tunnel is essential in order to avoid complications and to ensure optimal patient outcome. An understanding of the contents and their positions and relationships to each other allows the surgeon to perform a correct approach and accurately identify structures during procedures at or near the carpal tunnel.

Acknowledgment

The authors greatly acknowledge the Suprita M. Bandi Department of Physics Karnataka state women's University Bijapur, Karnataka, India for her technical assistance in this study.

REFERENCES

- [1] Williams PL, Bannister LH, Berry MM, *et al.*: Gray's Anatomy. 38th edition. Churchill Livingstone London. **1995**:861-2.
- [2] Bryce TH, Schafer ES. Quains Elements of Anatomy in Myology. 11th edition Longmans Green And Co, New York; **1923**, pg 134.
- [3] Potu BK, Gorantla VR, Rao MS, *et al.* *j.morpho.* **2008**.04.006
- [4] Lipscomb PR. *J Bone Joint Surg Am.* **1960**; 42:1058-61.
- [5] Jones BV. *J Bone Joint Surg Br.* **1959**; 41:763-5.
- [6] Ashby BS. *J Bone Joint Surg Br.* **1964**; 46:230-2.
- [7] M.L. Ajmani. *Iranian Red Crescent Medical Journal*, 3, **2001**, 20–25.
- [8] H.J. Mehta and W.U. Gardner. *American Journal of Anatomy*, 109, **1961**, 227–238.
- [9] S.D. Joshi, S.S. Joshi, *et al.* *Journal of Anatomical Society of India*, 54, **2005**, 12-15.
- [10] M.A. Entin. *Surgical Clinics of North America*, 48, **1968**, 1097-1112.
- [11] T.K. Cobb, K.N. An, *et al.* *Journal of hand Surgery*, 19, **1994**, 434-438.